



Over-expression of Heat Shock Protein 90 Reduces the Severity of Carbon Tetrachloride Hepatotoxicity in Rats

Joshua Joseph Malago*

*Department of Veterinary Anatomy and Pathology, College of Veterinary Medicine and Biomedical Sciences,
Sokoine University of Agriculture, P.O. Box 3203, Morogoro, Tanzania
Email: malagojj@yahoo.com*

Abstract

Cellular response to stress leads to production of heat shock proteins (Hsps) that are protective against various perturbations including stress, infection and inflammation. The liver is a victim to many body disturbances including intoxications and systemic diseases. Stemming on the ability of Hsps to protect an array of perturbations in various body systems, it is justifiable to explore their protective potency to the rat model of carbon tetrachloride (CTC)-induced hepatic toxicity. The current study therefore aimed at testing whether prior induction of Hsp90 could protect the liver against CTC. Rats were exposed to zinc sulphate (ZS) to induce Hsp90 then CTC for 8, 24, 48 or 72 hr. At the end of treatment, rats were sacrificed, autopsied, liver samples taken and fixed in formalin and routinely processed. Sectioned tissues were stained with hematoxylin and eosin or anti-Hsp90 monoclonal antibodies to assess morphological changes and Hsp90 expression respectively. CTC induced damage to the liver that was reduced by ZS. The ZS-mediated reduction of CTC-induced hepatic damage matched with ZS-induced over-expression of Hsp90. It is concluded that over-expression of Hsp90 is beneficial against CTC-induced hepatotoxicity.

Keywords: Carbon tetrachloride; Zinc sulphate; Hsp90; protection; rats.

* Corresponding author.

1. Introduction

The heat shock response is a highly conserved reaction exhibited by most mammalian cells to protect cells from stresses. The response is induced by various stress-related events whereby most cells and organisms react by rapid synthesis of a group of evolutionary conserved proteins ranging in size from 8 to 150 kDa termed the heat shock proteins (Hsps) [1,2]. They are named and classified according to their molecular weights with major Hsp families being HSP150, HSP110, HSP90, HSP70, HSP60, HSP40, HSP20, and HSP8.5 [3]. Other non-thermal stress including heavy metals like sodium arsenite and zinc ions have also been shown to induce the heat shock response [1]. The produced Hsps aim at protecting cells by rescuing proteins as well as protecting against stress, infection, inflammation and toxicity including hepatotoxicity [4]. They act as chaperones through protein-protein interaction to protect the already synthesized proteins against further injury [5, 6].

The liver is a predominant organ playing a pivotal role in regulating various physiological processes in the body like metabolism, secretion, storage as well as detoxification of substances. Because of that, it is frequently exposed to toxins, which in most cases affect cells that are equipped with detoxifying enzymes. A well-studied model of hepatotoxicity is the rat model of carbon tetrachloride (CTC). CTC induces liver damage mediated through lipid peroxidation by free radicals [7] which leads to cell necrosis followed by regeneration [8]. The CTC-induced peroxidation is due to oxidative stress and the subsequent formation of reactive oxygen intermediates. These intermediate lipoperoxides and free peroxide radicals are highly reactive and cause liver injury or necrosis [9]. Histologically, CTC-induced hepatic toxicity is manifested by fatty change, hepatocytic swelling, hepatocytic nuclear fragmentation, edema, necrosis and appearance of inflammatory areas with lymphocytic infiltration particularly around the hepatic central vein, and loss of hepatocytes [10, 11). Persistent insult triggers fibrosis which is vivid in chronic stage of the intoxication.

Several studies have indicated the protective role of Hsps against CTC intoxication in experimental animals. A study conducted by Lee and colleagues [4] demonstrated that rats treated with CTC show increased production of cytosolic Hsp70 and Hsp90. Although the produced Hsps enable the cells to survive during stress and promote the resumption of normal cellular activities in the recovery period [12, 13], cells still do not benefit wholly from the CTC-induced Hsps. As a result, liver damage following CTC exposure is a common course. One of the reasons for the failure of complete protection by Hsps is that the CTC-induced Hsps come too late to rescue the damaged cells since they are concurrently produced during the stress episode. Most likely, cells would benefit more from Hsps if these Hsps are produced earlier and far in advance of the stress as indicated earlier [14]. Thus, by considering the ability of heat shock response to confer protection against peroxidation in the liver [15, 16] and the fact that Hsps could best benefit cells when induced prior to stressors [14], it is of interest to explore whether zinc sulphate (ZS), which is a potent inducer of the heat shock response is beneficial against CTC hepatotoxicity.

2. Materials and methods

2.1. Laboratory animals

A total of 56 (Table 1) 21 week old male Wistar rats (Sokoine University of Agriculture, Morogoro, Tanzania)

weighing 138.7-221.6 g were used. They were kept in cages in a restricted access room with controlled room temperature and 12 h light/dark cycle. After 2 weeks of acclimatization, the rats were labeled and randomly allocated in 6 groups of 4-16 animals and kept up to 12 animals per cage in multiples of 4. Standard laboratory diet and safe drinking water were made available *ad-libitum*. The study was approved by the Faculty of Veterinary Medicine Undergraduate Studies Committee of the Sokoine University of Agriculture, Morogoro, Tanzania.

2.2. Animal groups and treatments

Treatments to the animal groups were done as indicated in Table 1. All injections were done intraperitoneally at 1 ml. Control groups received injection water (group 1) or olive oil (vehicle for CTC) (group 2). Rats in group 3 were given 50% CTC in olive oil (Well's, Madrid, Spain). Those in group 4 received 10 mg/kg of ZS (Techno Pharmachem, India). The effect of ZS on CTC intoxication was assessed by subsequently exposing rats to CTC following 8 hr (group 5) or 24 hr (group 6) of recovery from ZS. Animals were then humanely sacrificed at 8, 24, 48, or 72 hr of the experiment by over dosage of chloroform.

Table 1: Experimental groups and treatments

Group	Treatment	Animals used				
		8 h	24 h	48 h	72 h	Total
1	Control: Injection water	-	-	-	4	4
2	Control: Olive oil	-	-	-	4	4
3	CTC	-	4	4	4	12
4	ZS	4	4	4	4	16
5	ZS followed by CTC after 8 h	-	4	4	4	12
6	ZS followed by CTC after 24 h			4	4	8
Total animals		4	12	16	24	56

CTC, carbon tetrachloride; ZS, zinc sulphate

2.3. Histological evaluation of CTC hepatotoxicity

The humanely sacrificed rats were opened by midline laparotomy. The liver was accessed and observed for any abnormalities. Subsequently, pieces of the liver were taken, fixed in 10% neutral buffered formalin and processed routinely. Sectioning was done to obtain 4 μ m thick tissue sections to be used for histology and immunohistochemistry. For histological evaluation of liver damage, the obtained tissue sections were stained with haematoxylin and eosin (HE) and the CTC-induced toxic changes were assessed blindly and quantitated by two independent pathologists. The quantification was performed by measuring the area of necrosis surrounding the central vein (centrilobular necrosis) or portal triad (portal necrosis) and that extending throughout the lobule using a standalone system of DP21 microscope digital camera (Olympus, Japan). Obtained data were expressed as percentage lobular necrosis.

2.4. Immunohistochemistry

2.4.1. Subbing of microscopic slides

To prevent detachment of tissue sections during immunohistochemistry procedures, microscopic slides were subbed in chrome-gelatin (10 g of gelatin and 1 g $\text{CrK}(\text{SO}_4)_2 \cdot 12\text{H}_2\text{O}$ in 1 l of warm non-boiling distilled water). After stirring until dissolved, a thymol crystal was added and the solution was allowed to cool before further dissolving 0.188 g $\text{CrK}(\text{SO}_4)_2 \cdot 12\text{H}_2\text{O}$ in the solution. The slides were then soaked in soap solution for 1 hr, rinsed in distilled water that was changed several times, dipped in the subbing solution and drained in a paper towel to allow drying. When thoroughly dry, the slides were stored in slide boxes until use.

2.4.2. Deparaffinization and sections to water

The obtained 4 μm thick tissue sections were applied to the subbed slides. They were then deparaffinized in xylene (3 times, 5 min each) then hydrated in descending ethanol of absolute and 95% (2 changes each solution, 10 min each change) followed by distilled water (1 min with agitation). Any excess liquid on slides was aspirated.

2.4.3. Antigen unmasking (heat induced epitope retrieval)

To unmask antigens, the sections were covered with 10 mM sodium citrate buffer (pH 6.0) and heated at 95°C for 5 min. Heating was repeated after topping off the sections with fresh buffer before cooling (room temperature, 20 min) in the same buffer. The sections were then washed in distilled water (3 changes, 2 min each) and any excess liquid was aspirated from the slides.

2.4.4. Quenching endogenous peroxidase activity

Endogenous peroxidases were inactivated by incubating the sections in 3% hydrogen peroxide in distilled water for 10 min followed by washing (3 changes, 5 min each) in phosphate-buffered saline (PBS) (0.01M Na_2HPO_4 , 0.01M NaH_2PO_4 , 0.9% (w/v) NaCl; pH 7.3).

2.4.5. Immunoperoxidase staining using Horseradish peroxidase-Streptavidin system

Immunostaining was done by Horseradish peroxidase-Streptavidin system using SPlink HRP detection bulk kit (GBI Labs, Mukilteo, WA, USA, Cat No D01-60) according to manufacturer's recommendations. Tissue sections were incubated for 10 min in ready for use pre-blocking solution and then blotted to remove any excess pre-blocking solution. Subsequently, the sections were incubated in a humid chamber with monoclonal Hsp90 (Novus biological, Littleton, CO, USA) (diluted in 2% normal blocking goat serum in PBS) for 60 min at room temperature. The sections were then rinsed in PBS (3 changes, 2 min each), incubated (10 min) in broad spectrum biotinylated secondary antibody and rinsed in PBS (3 changes, 2 min each). They were then incubated in HRP-Streptavidin (10 min, room temperature), washed in PBS (3 changes, 5 min each) and incubated in DAB+ enzyme (premixed 3,3-diaminobenzidine plus) (GBI Labs, Mukilteo, WA, USA, Cat No C09-12) for 5 min or until desired colour was attained. The sections were then counterstained in hematoxylin (20 sec) and

immediately rinsed thoroughly in tap water (about 2 min) and blued in PBS (60 sec) before rinsing in distilled water. Subsequently, the sections were dehydrated in ascending ethanol (95% then absolute, 2 changes each solution, 10 sec each change) and dipped in xylene (3 changes, 10 sec each). The sections were then mounted with DPX, examined under light microscope (Olympus BX 41, Japan) and photographs taken by DP21 camera (Olympus).

2.5. Statistical analysis

Statistical significant between the mean values of control and those for CTC-, ZS-, ZS and CTC-treated rats was assessed by one way ANOVA with comparison of means. The differences were considered significant at $p < 0.05$ level using the Student's t-Test. All numerical values are presented as mean \pm SEM.

3. Results

3.1. Induction of hepatotoxicity by CTC

Administration of CTC to rats for 8 hr resulted into nuclear condensation or pyknosis (nuclei are decreased in size, roundish, homogeneous, conspicuous stained, and lack nucleoli and chromatin granules) with less dense cytoplasm (cytoplasmolysis), mild vacuolarization and necrosis, particularly around the central vein (centrilobular necrosis) (Figure 1). After 24 hr, CTC induced massive haemorrhage, centrilobular necrosis and vesicular fatty change (both micro and macro) in the midzonal and periportal areas of hepatic lobules (Figure 2). The haemorrhage and necrosis were more extensive after 48 hr to involve the midzonal area while sparing small area around the portal triad. In some areas this necrosis extended to join adjacent central veins (centro-central bridging) (Figure 3). Bridging necrosis involving central veins (centro-central), portal areas (porto-portal) and central veins and portal area (centro-portal) was obvious after 72 hr exposure to CTC. At this time, the necrosis involved the whole liver lobule except for small portions that were surrounded by the bridging necrosis (Figure 4). Hepatocytes in these latter areas were nevertheless undergoing necrosis. Histological sections of control rats showed mild congestion and a normal organ architecture (Figure 5).

3.2. Effect of ZS on CTC hepatotoxicity

The effect of CTC after prior induction of ZS for 8 hr is shown in Figure 6 to 8. Figure 6 indicates that 8 hr exposure to CTC led to mild degenerative changes exhibited by dense cytoplasm and retention of vesicular nuclei containing nucleoli that were lost in their counterparts devoid of ZS (Figure 1). The 8 hr exposure to ZS also reduced the magnitude of necrosis in rats subsequently exposed to CTC for 24 hr but showed both micro- and macro- vesicular fatty changes (Figure 7). There was mild haemorrhage and no obvious necrosis in these animals as opposes to their counterparts not receiving ZS (Figure 2). When the exposure to CTC was extended to 48 hr, there was a reduction in the severity and extent of haemorrhage and necrosis. In this case, the lesion was less haemorrhagic and could hardly cause bridging of adjacent central veins (Figure 8) contrary to the lesion in rats without ZS pre-treatment (Figure 3). At 72 hr CTC exposure, pre-treatment with ZS for 8 hr led to mild or no bridging at all (Figure 9) as opposes to extensive bridging necrosis in rats devoid of ZS (Figure 4).

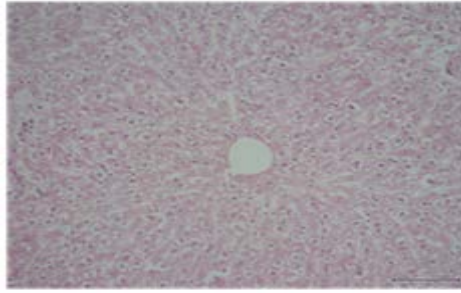


Figure 1: Nuclear condensation and mild necrosis. CTC 8 hr, HE, 100x

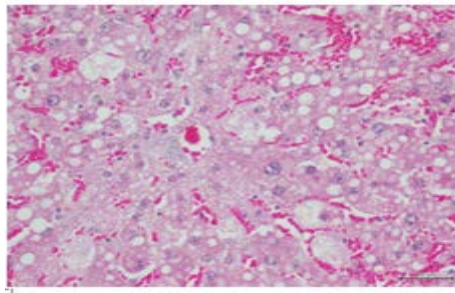


Figure 2: Haemorrhage, vacuolarization and necrosis. CTC 24 hr, HE, 200x

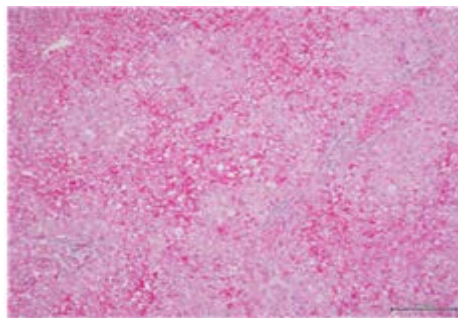


Figure 3: Severe haemorrhage and bridging necrosis. CTC 48 hr, HE, 100x

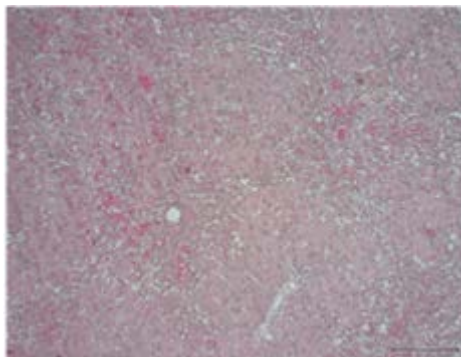


Figure 4: Severe bridging necrosis. CTC 72 hr, HE, 100x

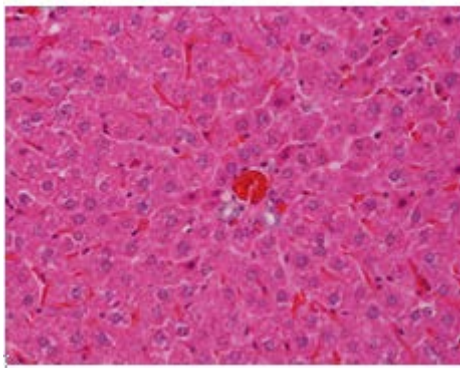


Figure 5: Congestion. Control. HE, 200x

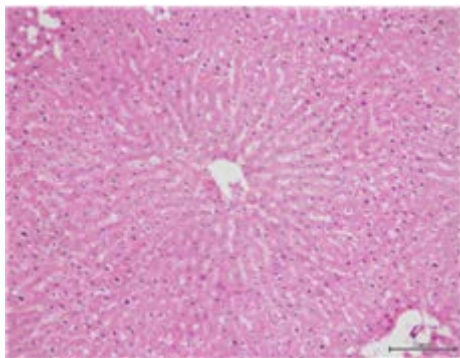


Figure 6: Mild centrilobular necrosis. ZS 8 hr CTC 8 hr, HE, 100x

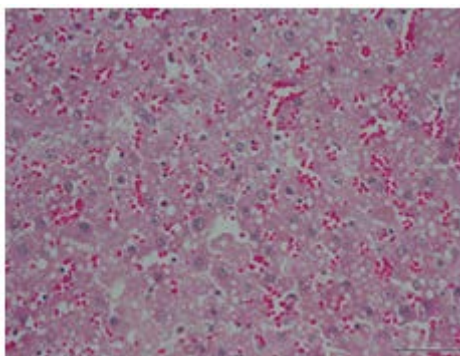


Figure 7: Haemorrhage and vacuolation. ZS 8 h CTC 24 h, HE, 200x

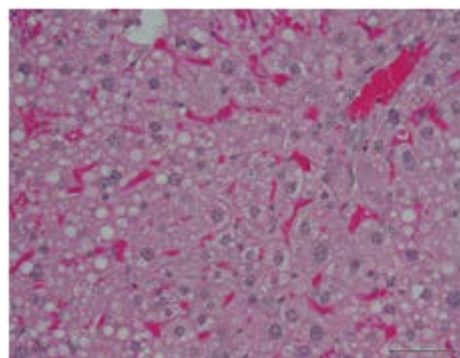


Figure 8: Micro and macrovesicles. ZS 8 hr CTC 48 hr, HE, 400x

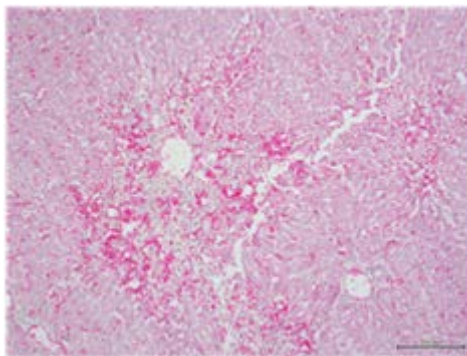


Figure 9: Mild bridging necrosis. ZS 8 hr CTC 72 hr, HE, 100x

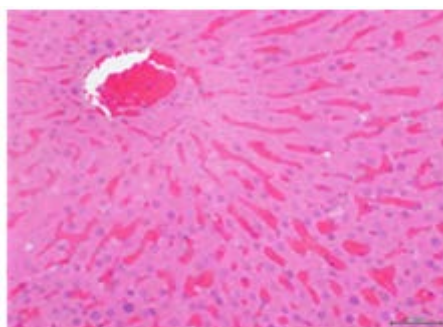


Figure 10: Congestion, condensed nuclei. ZS 24 h CTC 8 h, HE, 200x

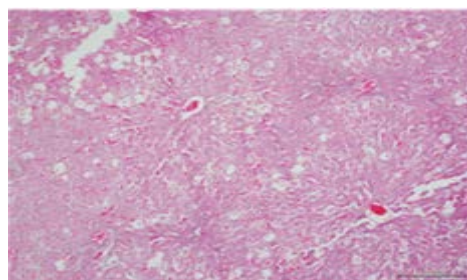


Figure 11: Vacuolarisation and necrosis. ZS 24 hr CTC 24 hr, HE, 100x

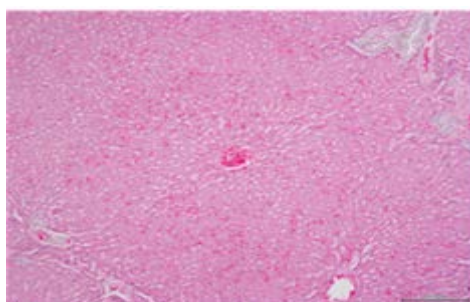


Figure 12: Haemorrhage and necrosis. ZS 24 hr CTC 48 hr, HE, 100x

Figure 1-12: Rats were treated with carbon tetrachloride (CTC) after or without prior treatment (8 or 24 hr) with zinc sulphate (ZS) and sacrificed after 8, 24, 48 or 72 hr. Each photomicrograph is a representative of 4 rats. HE, Haematoxylin and Eosin

The protective effect of the 24 hr exposure of rats to ZS over CTC for 8, 24, or 48 hr is indicated in Figures 10, 11, and 12. Figure 10 shows that 8 hr exposure to CTC led to severe congestion and nuclear condensation but with retained nucleoli and dense cytoplasm as opposes to rats devoid of ZS (Figure 1). As depicted in Figure 11, mild haemorrhage and congestion together with ballooning of hepatocytes, predominate the lesion of 24 hr exposure to CTC subsequent to ZS. Indeed, this lesion depicts a marked reduction in severity of CTC hepatotoxicity when compared to similar lesion observed in rats devoid of ZS (Figure 2). The exposure to CTC for 48 hr subsequent to 24 hr of ZS reduced the severe massive haemorrhage and necrosis of rats (Figure 3) to a moderate haemorrhage and mild necrosis (Figure 12). The necrosis was centrilobular and midzonal whereas haemorrhage was diffused throughout the lobule. The 24 hr exposure to ZS was also capable of reducing the severity of 72 hr exposure of rats to CTC exhibited by small extent of bridging necrosis (data not shown).

3.3. Scores of necrotic area

The size of necrotic area induced by CTC in the hepatic lobule surrounding and extending from the central vein or portal triad significantly increased with time. That of centrilobular necrosis increased from about 17% after 8 hr to 90% after 72 hr (Figure 13) whereas that of portal necrosis was from 10% after 8 hr to 90% after 72 hr (Figure 14). Both Figure 13 and 14 indicate that prior treatment of rats with ZS for 8 or 24 hr did not significantly reduce the size of hepatic necrosis after 8 hr of CTC treatment. The protective effect of ZS was clearly manifested after 24 hr of CTC treatment. At this time, approximately one-third (60% to 40%) and two-thirds (60% to 20%) of the CTC-induced centrilobular necrotic areas were reduced by 8 and 24 hr treatment with ZS, respectively (Figure 13). After 48 hr of CTC administration, the size of the liver lobule that underwent necrosis was about 88%. This area was significantly reduced to 30% or 10% by prior administration of ZS for 8 or 24 hr, respectively. A more or less similar reduction in necrosis was vivid after 72 hr of CTC administration (Figure 13).

According to Figure 14, about two-thirds (30% to 10%) of the 24 hr CTC-induced portal necrotic areas were reduced by 8 and 24 hr treatment with ZS (Figure 14). After 48 hr of CTC administration, the size of portal necrosis was about 82%. This area was significantly reduced to 18% or 10% by prior administration of ZS for 8 or 24 hr, respectively. A more or less similar reduction in necrosis was vivid after 72 hr of CTC administration following 8 hr of ZS but reduced to almost 0% by 24 hr ZS (Figure 14).

In addition, Figures 13 and 14 show that there was a significant difference in the potency of preventing CTC hepatic necrosis between 8 and 24 hr of ZS treatment. The difference was vivid after 24, 48 and 72 hr of CTC exposure whereby administration of ZS 24 hr prior to CTC was more potent in reducing hepatic necrosis than 8 hr administration.

3.4. Expression of Hsp90 by ZS

To explore the potential of ZS to induce production of Hsp90, initially constitutive expression of this Hsp was assessed and observed a mild expression of the protein (Figure 15). Following ZS treatment, the expression of Hsp90 showed a time-dependent course. The expression was moderate after 8 hr (Figure 16) followed by intense

after 24 hr (Figure 17). The expression intensity peaked up at 48 hr (Figure 18) after which it declined to moderate at 72 hr (Figure 19). When compared to the histological changes, the expression was corresponding the the protective potency of ZS at various time points.

3.5. Expression of Hsp90 by ZS on CTC

To better understand the significance of the induction of Hsp90, the effect of pre-induction of the chaperones on CTC-induced liver damage was analyzed. This was done by assessing the expression of Hsp90 in rats receiving both ZS and CTC treatments and subsequently evaluating the degree of hepatic damage. Exposure of rats to ZS for 8 hr followed by another 8 hr of CTC resulted in mild diffusely distributed expression of Hsp90 in the organ (Figure 20). After 24 hr of CTC, the expression of Hsp90 increased in intensity and distribution (Figure 21). After 48 hr, a faint diffuse expression of Hsp90 was observed (Figure 22). At 72 hr exposure to CTC the observed faintly staining of Hsp90 was becoming unevenly diffused in the organ (Figure 23).

Expression of Hsp90 after 24 hr treatment of rats with ZS followed by CTC for 8, was intense and diffused throughout the lobule (Figure 24). After 24 hr of CTC treatment, the expression was moderate and diffused (Figure 25). Following 48 or 72 hr of CTC treatment, the expression of Hsp90 was intense and diffused in the lobule (Figure 26).

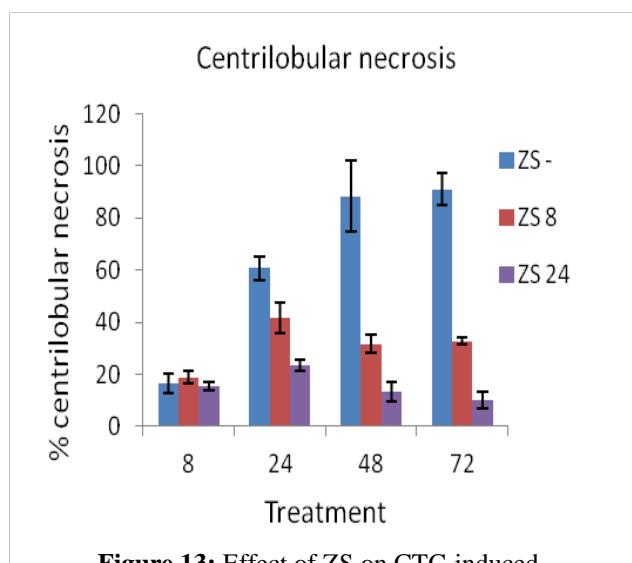


Figure 13: Effect of ZS on CTC-induced centrilobular necrosis. Rats were exposed to ZS for 8 or 24 h followed by CTC for 8, 24, 48 or 72 h. The circular necrotic area extending from central vein was measured in 4 rats for 4 sections in each rat. Data indicate mean±SD. Significant values were established at $p \leq 0.05$. ZS-, rats exposed to CTC alone; ZS, Zinc sulphate; CTC, carbon tetrachloride

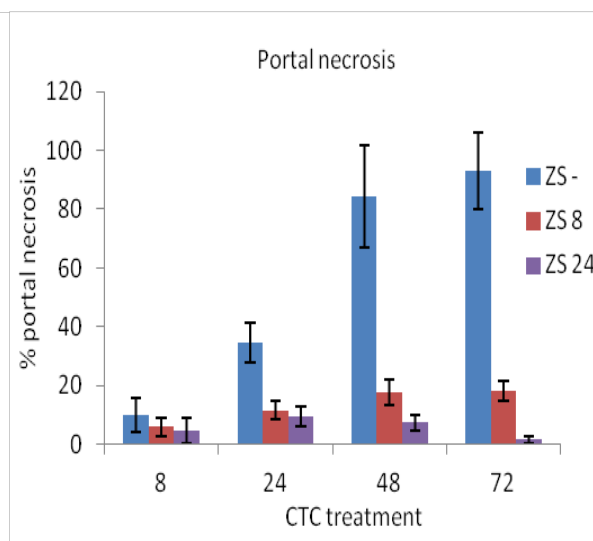


Figure 14: Effect of ZS on CTC-induced portal necrosis. Rats were exposed to ZS for 8 or 24 h followed by CTC for 8, 24, 48 or 72 h. The circular necrotic area extending from portal triad was measured in 4 rats for 4 sections in each rats. Data indicate mean±SD. Significant values were established at $p \leq 0.05$. ZS-, rats exposed to CTC alone; ZS, Zinc sulphate; CTC, carbon tetrachloride

4. Discussion

The rat model of CTC hepatotoxicity has extensively been studied. Exposure of rats to CTC results into lipid peroxidation by free radical derivatives of CTC which lead to fatty changes in the liver, swelling, inflammation and cell damage that culminates into hepatic necrosis [11]. Depending on the dosage and duration of exposure, the pathological lesion may be acute or chronic. Both acute and chronic CTC-induced tissue injuries are mediated through bioactivation of phase 1 cytochrome P₄₅₀ system to form reactive metabolic trichloromethyl radicals (CCl₃) and peroxytrichloromethyl radicals (OOCCL₃). Consequently these free radicals can covalently bind to macromolecules such as proteins, lipids and nucleic acids. The final outcome is an increase in lipoperoxide and free peroxide radical concentration that are highly reactive and cause injury or necrosis [9]. The acute histological lesion of CTC is featured by haemorrhage, degeneration of hepatocytes, fatty change, and necrosis, whereas chronic lesion is characterized mainly by hepatic fibrosis. The acute lesion may be limited to hepatocytes around central veins or spread to midzone or entire lobule [17, 18]. Consistently, this current study has reproduced the acute model of CTC hepatotoxicity (Figure 1-4). These lesions were exhibited in all rats receiving CTC and varied in respect to the duration of exposure to the toxin.

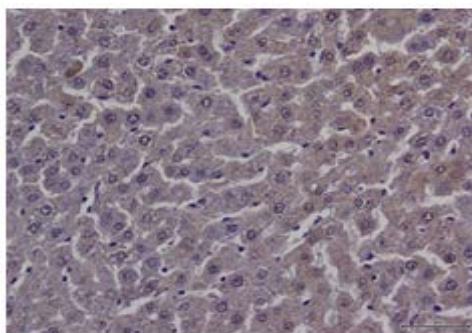


Figure 15: Hsp90, constitutive mild expression. Control. IHC, 200x

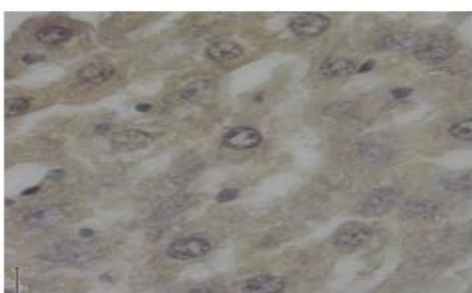

Figure 16: Hsp90 moderate expression. ZS 8 hr, IHC, 1000x

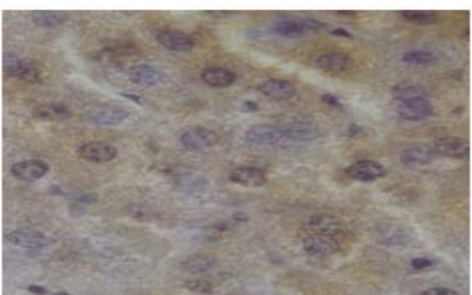


Figure 17: Hsp90 intense expression. ZS 24 hr, IHC, 600x

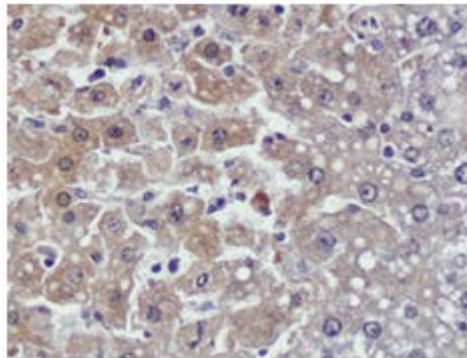


Figure 18: Hsp90 intense expression. ZS 48 hr, IHC, 200x

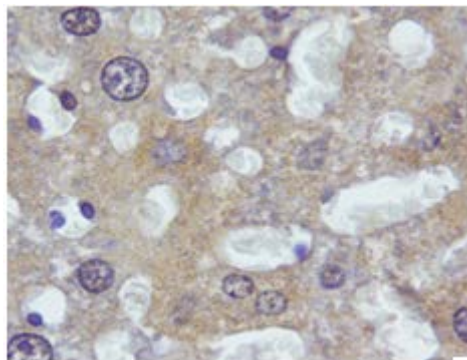


Figure 19: Hsp90 moderate expression. ZS 72 hr, IHC, 600x

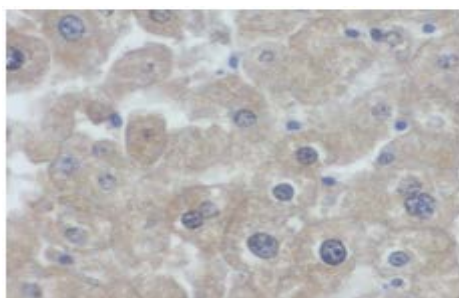


Figure 20: Hsp90 faint diffuse expression. ZS 8 hr CTC 8 hr, IHC, 400x

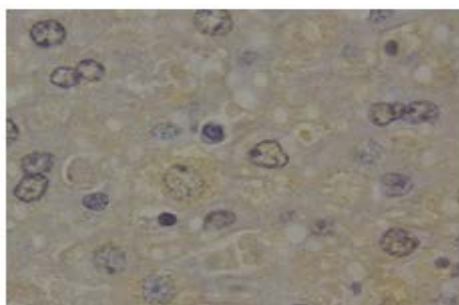


Figure 21: Hsp90 moderate expression. ZS 8 h CTC 24 hr, IHC, 600x

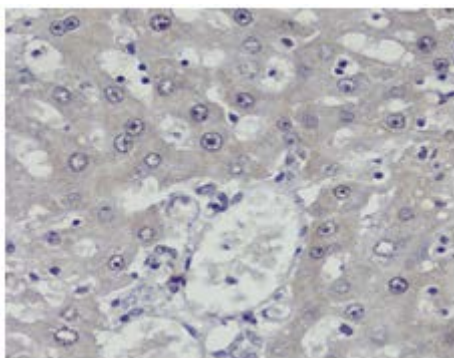


Figure 25 : Hsp90 faint diffuse expression. ZS 8 hr CTC 48 h, IHC, 200x

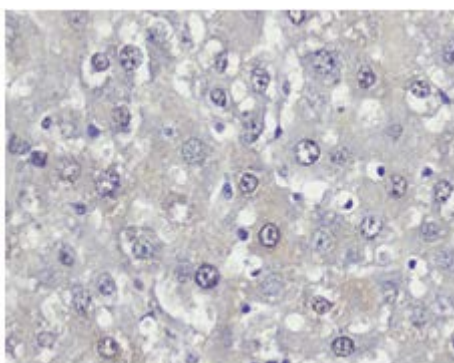


Figure 23: Hsp90 faint uneven expression. ZS 8 hr CTC 72 h, IHC, 400x

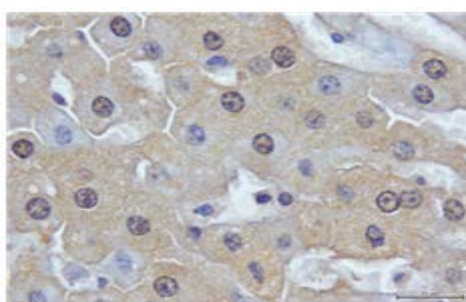


Figure 24: Hsp90 intense expression. ZS 24 hr CTC 8 hr, IHC, 600x

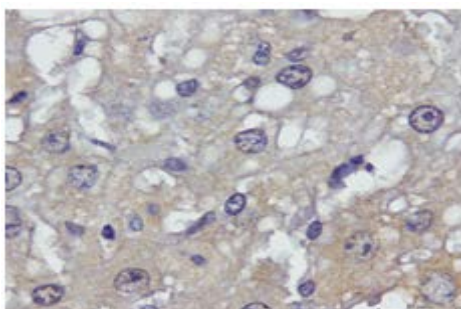


Figure 25: Hsp90 moderate expression. ZS 24 hr CTC 24 hr, IHC 600x

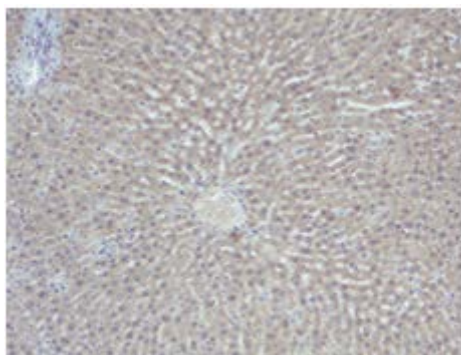


Figure 26: Hsp90 intense expression. ZS 24 hr CTC 48 hr, IHC 100x

Figure 15-26: Rats were treated with carbon tetrachloride (CTC) after or without prior treatment (8 or 24 hr) with zinc sulphate (ZS) and sacrificed after 8, 24, 48 or 72 hr. Each photomicrograph is a representative of 4 rats. HE, Haematoxylin and Eosin; IHC, Immunohistochemistry

Data presented in this study also shows that ZS pre-treatment to rats reduced the severity of liver damage. The reduction was found to be significant ($p < 0.05$) when the necrotic areas were scored (Figure 13 and 14). This reduction correlated with over-expression of Hsp90. Induction of heat shock response culminates in over-expression of Hsps, which have remained remarkably conserved, ranging in size from 8kDa to 150 kDa molecular weight. They are involved in coping with chemical and physical stress in all living cells [7, 19]. Thus, their expression is usually associated with protection against various disorders. It is therefore possible that the expression of Hsp90 observed in this study could be linked with the protective ability of ZS against CTC. The potential of ZS to induce production of Hsps has been reported [20]. ZS has been observed to induce expression of Hsps and to confer protection against various organs including the liver, in both *in vivo* and *in vitro* systems against different conditions [21, 22]. The current study adds to the existing knowledge that ZS, possibly via over-expression of Hsp90 can confer protection against CTC-induced hepatotoxicity.

The significance of Hsps in hepatic protection against CTC has been demonstrated by some scholars. They reported that production of Hsp5 by dioscin protected mice against CTC-induced acute liver damage [23]. In another study, a commercial herbal product Wei Kang Su induced production of Hsp25 and Hsp70, enhanced mitochondrial antioxidant status and protected rats against CTC hepatotoxicity [24]. Further, Yamamoto and colleagues [25] reported that heat shock conditioning by hyperthermia at 48 hr recovery leads to over-expression of Hsp72. The produced Hsp72 protects the liver against CTC-induced injury.

5. Conclusion

The induction and subsequent protective role of heat shock response have been extensively evaluated in various systems and disorders. The data presented in this study extends further the fact that Hsps, particularly Hsp90, are produced by rat hepatocytes during administration of ZS. The animals could benefit from the response by

earlier induction of the protein before stress. Indeed, the Hsp90 induction by ZS observed in this study was a preconditioning response to prepare the subjects against the impending CTC stress. This preconditioning response may play a vital role in the health of an individual. For instance, by considering the importance of zinc as an essential element to the body for various metabolic processes, individuals with enough dietary zinc intakes could be in a beneficial side when exposed to hepatotoxins as opposes to deficient subjects. It could be of interest to explore further the relationship between zinc, as an essential mineral element in the body and its protective role against hepatotoxins and toxicity to other body systems.

6. Recommendation

The current study had appreciated the protective potency of ZS against CTC hepatotoxicity in rats. It appears that this protection is mediated through over-expression of Hsp90. Since zinc is a trace element needed for body functioning, its protection against CTC hepatotoxicity points to an additional benefit of this element in the body, particularly in overcoming hepatic toxicity. In addition, the observation that the protective role is partly mediated through production of Hsps, suggests that individuals can benefit from dietary heat shock response inducers like Vitamin B6 and butyric acid that can potentially protect against hepatotoxins. This calls for more research in this line.

7. Limitations of the study

- The induced Hsp90 is just one of several other Hsps that can also contribute to protection. Further studies are needed to explore the contribution of other Hsps to arrive to a conclusion on the protective role of the heat shock response.
- ZS can mediate protection against CTC through other unknown mechanisms than Hsp90 production. Thus, interpretation of the current findings should be done cautiously.

References

- [1]. J.J. Malago, J.F.J.G. Koninkx, J.E. van Dijk. "The heat shock response and cytoprotection of the intestinal epithelium." *Cell Stress Chaperones*, vol. 7 pp. 191-199, Apr. 2002.
- [2]. C. Wu. "Heat shock transcription factors: Structure and regulation." *Annu. Rev. Cell Dev. Biol.*, vol. 11 pp. 441-469, 1995.
- [3]. J.Y. Kim, M.A. Yenari. "The immune modulating properties of the heat shock proteins after brain injury." *Anat. Cell Biol.*, vol. 46 pp. 1-7, Mar. 2013.
- [4]. K.J. Lee, K. Terada, S. Oyadomari, Y. Inomata, M. Mori, T. Gotoh. "Induction of molecular chaperones in carbon tetrachloride-treated rat liver: implications in protection against liver damage." *Cell Stress Chaperones*, vol. 9 pp. 58-68, Mar. 2004.
- [5]. D.D. Mosser, A.W. Caron, L. Bourget, A.B. Meriin, M.Y. Sherman, R.I. Morimoto, et al. "The chaperone function of hsp70 is required for protection against stress-induced apoptosis." *Mol. Cell Biol.*, vol. 20 pp. 7146-7159, Oct. 2000.
- [6]. I. Hostein, D. Robertson, F. DiStefano, P. Workman, P.A. Clarke. "Inhibition of signal transduction by

- the Hsp90 inhibitor 17-allylamino-17-demethoxygeldanamycin results in cytostasis and apoptosis.” *Cancer Res.*, vol. 61 pp. 4003-4009, May 2001.
- [7]. R. Krithika, R. Verma, P. Shrivastav. “Antioxidative and cytoprotective effects of andrographolide against CCl₄-induced hepatotoxicity in HepG2 cells.” *Hum. Exp. Toxicol.*, vol. 32 pp. 530-543, May 2013.
- [8]. S.K. Sharma, Suman, N. Vasudeva. “Hepatoprotective activity of *Vitis vinifera* root extract against carbon tetrachloride-induced liver damage in rats.” *Acta Pol. Pharm.*, vol. 69 pp. 933-937, Sep. 2012.
- [9]. R.A. Khan, M.R. Khan, S. Sahreen. “CCl₄-induced hepatotoxicity: protective effect of rutin on p53, CYP2E1 and the antioxidative status in rat.” *BMC Complement Altern. Med.*, vol. 12 pp. 178, Oct. 2012.
- [10]. A.A. Adeneye. “Protective activity of the stem bark aqueous extract of *Musanga cecropioides* in carbon tetrachloride- and acetaminophen- induced acute hepatotoxicity in rats.” *Afr. J Tradit. Complement Altern. Med.*, vol. 6 pp. 131-138, Mar. 2009.
- [11]. S. Babitha, D. Banji, O.J. Banji. “Antioxidant and hepatoprotective effects of flower extract of *Millingtonia hortensis* Linn on carbon tetrachloride-induced hepatotoxicity.” *J. Pharm. Bioallied. Sci.* vol. 4 pp. 307-312, Oct. 2012.
- [12]. R. Palotai, M.S. Szalay, P. Csermely. “Chaperones as intergrators of cellular networks: changes of cellular integrity in stress and diseases.” *IUBMB Life*, vol. 60 pp. 10-18, Jan. 2008.
- [13]. H.H. Kampinga, E.A. Craig. “The HSP70 chaperone machinery: J proteins as drivers of functional specificity.” *Nat. Rev. Mol. Cell Biol.*, vol. 11 pp. 579-592, Aug. 2010.
- [14]. J.J. Malago, J.F.J.G. Koninkx, H.H. Ovelgönne, F.J.A.M. van Asten, J.F. Swennenhuis, J.E. van Dijk. “Expression levels of heat shock proteins in enterocyte-like Caco-2 cells after exposure to *Salmonella enteritidis*.” *Cell Stress Chaperones*, vol. 8 pp. 194-203, Summer, 2003.
- [15]. E. Padmini, B. Vijaya Geetha. “Modulation of ASK1 expression during overexpression of Trx and Hsp70 in stressed fish liver mitochondria.” *Cell Stress Chaperones*, vol. 14 pp. 459-467, Sep. 2009.
- [16]. S.Y. Ye, J. Wu, J. Zhang, S.S. Zheng. “Locally synthesized HSP27 in hepatocytes: Is it possibly a novel strategy against human liver ischemia/reperfusion injury?” *Med. Hypotheses*, vol. 76 pp. 296-298, Feb. 2011.
- [17]. N. Hamdy, E. El-Demerdash. “New therapeutic aspect for carvedilol: antifibrotic effects of carvedilol in chronic carbon tetrachloride-induced liver damage.” *Toxicol. Appl. Pharmacol.*, vol. 261 pp. 292-299, Jun. 2012.
- [18]. T.W. Kim, J.H. Lim, I.B. Song, S.J. Park, J.W. Yang, J.C. Shin, et al. “Hepatoprotective and anti-hepatitis C viral activity of *Platycodon grandiflorum* extract on carbon tetrachloride-induced acute hepatic injury in mice.” *J. Nutr. Sci. Vitaminol.*, vol. 58 pp. 187-194, 2012.
- [19]. W.J. Welch. “Mammalian stress response: Cell physiology, structure/function of stress proteins, and implications for medicine and disease.” *Physiol. Rev.* vol. 72 pp. 1063-1081, Oct. 1992.
- [20]. W. van Molle, M. van Roy, T. van Bogaert, L. Dejager, P. van Lint, I. van Laere et al. “Protection of zinc against tumor necrosis factor induced lethal inflammation depends on heat shock protein 70 and allows safe antitumor therapy.” *Cancer Res.*, vol. 67 pp. 7301-7307, Aug. 2007.
- [21]. Y. Cheng, Y. Liu, J. Liang. “Zinc is a potent heat shock protein inducer during liver cold preservation

in rats.” *Chin. Med. J. (Eng I)*., vol. 115 pp. 1777-1779, Dec. 2002.

- [22]. R. Ambra, E. Mocchegiani, R. Giacconi, R. Canali, A. Rinna, M. Malavolta et al. “Characterization of the Hsp70 response in lymphoblasts from aged and centenarian subjects and differential effects of in vitro zinc supplementation.” *Exp. Gerontol.*, vol. 39 pp. 1475-1484, Oct. 2004.
- [23]. B. Lu, L. Yin, L. Xu, J. Peng. “Application of proteomic and bioinformatics techniques for studying the hepatoprotective effect of dioscin against CCl₄-induced liver damage in mice.” *Planta Med.*, vol. 77 pp. 407-415, Mar. 2011.
- [24]. P.K. Leong, N. Chen, P.Y. Chiu, H.Y. Leung, C.W. Ma, Q.T. Tang, et al. “Long-term treatment with shengmai san-derived herbal supplement (Wei Kang Su) enhances antioxidant response in various tissues of rats with protection against carbon tetrachloride hepatotoxicity.” *J. Med. Food*, vol. 13 pp. 427-438, Apr. 2010.
- [25]. H. Yamamoto, Y. Yamamoto, K. Yamagami, M. Kume, S. Kimoto, S. Toyokuni, et al. “Heat-shock preconditioning reduces oxidative protein denaturation and ameliorates liver injury by carbon tetrachloride in rats.” *Res. Exp. Med. (Berl)*., vol. 199 pp. 309-318, Jun. 2000.
- [26]. C. Hackl, A. Mori, C. Moser, S.A. Lang, R. Dayoub, T.S. Weiss, et al. “Effect of heat-shock protein-90 (HSP90) inhibition on human hepatocytes and on liver regeneration in experimental models.” *Surgery*, vol. 147 pp. 704-712, May 2010.
- [27]. J.Y. Song, L. Li, J.B. Ahn, J.G. Park, J.S. Jo, D.H. Park, et al. “Acute liver toxicity by carbon tetrachloride in HSP70 knock-out mice.” *Exp. Toxicol. Pathol.*, vol. 59 pp. 29-34, Sep. 2007.
- [28]. P.Y. Chiu, M.H. Tang, D.H. Mak, M.K. Poon, K.M. Ko. “Hepatoprotective mechanism of schisandrin B: role of mitochondrial glutathione antioxidant status and heat shock proteins.” *Free Radic. Biol. Med.*, vol. 35 pp. 368-380, Aug. 2003.
- [29]. J. Mayama, T. Kumano, M. Hayakari, T. Yamazaki, S. Aizawa, T. Kudo, et al. Polymorphic glutathione S-transferase subunit 3 of rat liver exhibits different susceptibilities to carbon tetrachloride: differences in their interactions with heat-shock protein 90. *Biochem. J.*, vol. 372 pp. 611-616, Jun. 2003.