



Gangrenous Cholecystitis Post Colonoscopy: a Case Report

Masimba Nyandowe *

The Townsville Hospital, 100 Angus Smith Drive, Douglas 4814, Queensland, Australia

Email: simbanyandowe@yahoo.com

Abstract

Acute cholecystitis after colonoscopy has been described in the literature through case reports but is still rare. We report the case of a female patient not previously known to have gallstones who underwent a colonoscopy for colonic polyp surveillance. Sessile polyps were retrieved. She represented 24 hours later with abdominal pain. Clinical imaging revealed cholecystitis. She underwent an uneventful laparoscopic cholecystectomy and later discharged home.

Keywords: cholecystitis; colonoscopy; complications.

1. Introduction

Colonoscopy is a common and safe procedure for investigation and management of gastrointestinal conditions. Complications are rare in general. Most patients have the procedure as a day case. Complications are usually minor with one study reporting gastrointestinal discomfort in 3.3% of patients[1]. The more severe complications of perforation and haemorrhage are even rarer. The literature describes about 10 cases of acute cholecystitis after colonoscopy with one of them being gangrenous cholecystitis[1, 2]. The mechanism still remains unknown.

2. Case report

A 57 year old female being followed up for previous colonic polyps underwent a surveillance colonoscopy. Her

two previous colonoscopies had been uneventful. On the current admission she was found to have sessile polyps in the descending colon which were resected and retrieved for histology. She was discharged on the same day. She represented to hospital 24 hours later with lower abdominal pain and vomiting. She denied any previous history of biliary colic and was not known to have gallstones. Examination revealed a soft but tender abdomen with guarding in the lower abdomen. She was not tender in the right upper quadrant and was murphy's negative. Laboratory tests revealed a normal white cell count of $7\ 000\ \text{mm}^2$; total bilirubin $14\ \mu\text{mol/L}$; gamma-glutamyl transferase $38\ \text{IU/L}$; alkaline phosphatase $60\ \text{IU/L}$. She underwent a computed tomography of the abdomen and pelvis to rule out a bowel perforation. This surprisingly revealed gallbladder wall thickening, pericholecystic fluid and fat stranding around the gallbladder. There was no pneumoperitoneum. An Ultrasound scan of the abdomen also showed cholelithiasis, 4mm thick gallbladder wall and pericholecystic fluid. The discrepancy between radiological findings and clinical examination resulted in the patient being admitted into hospital for observation. She went on to develop right upper quadrant pain overnight and fevers. She had a laparoscopic cholecystectomy which revealed a gangrenous gallbladder. The specimen, in addition to histology, was also sent for culture which grew *E. Coli*.

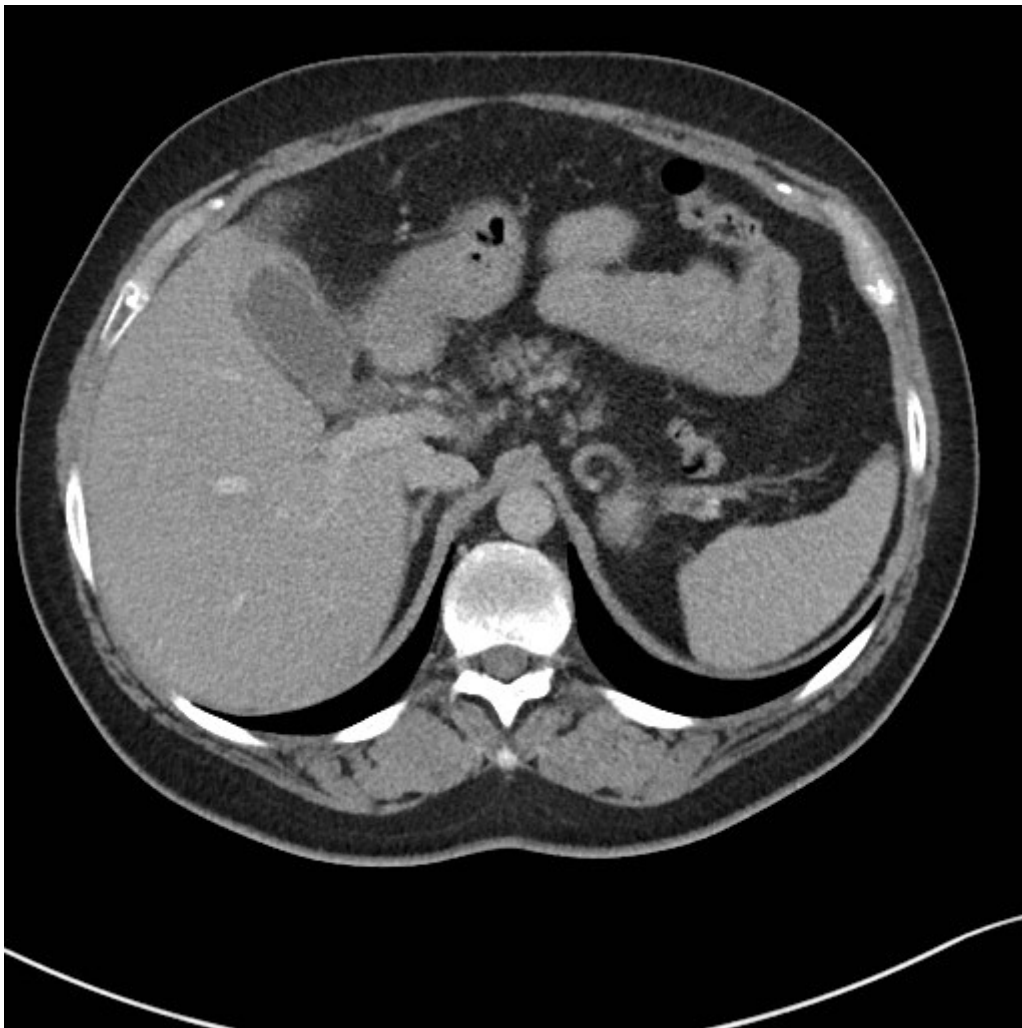


Figure 1: Computed tomography of the abdomen findings: acute cholecystitis.

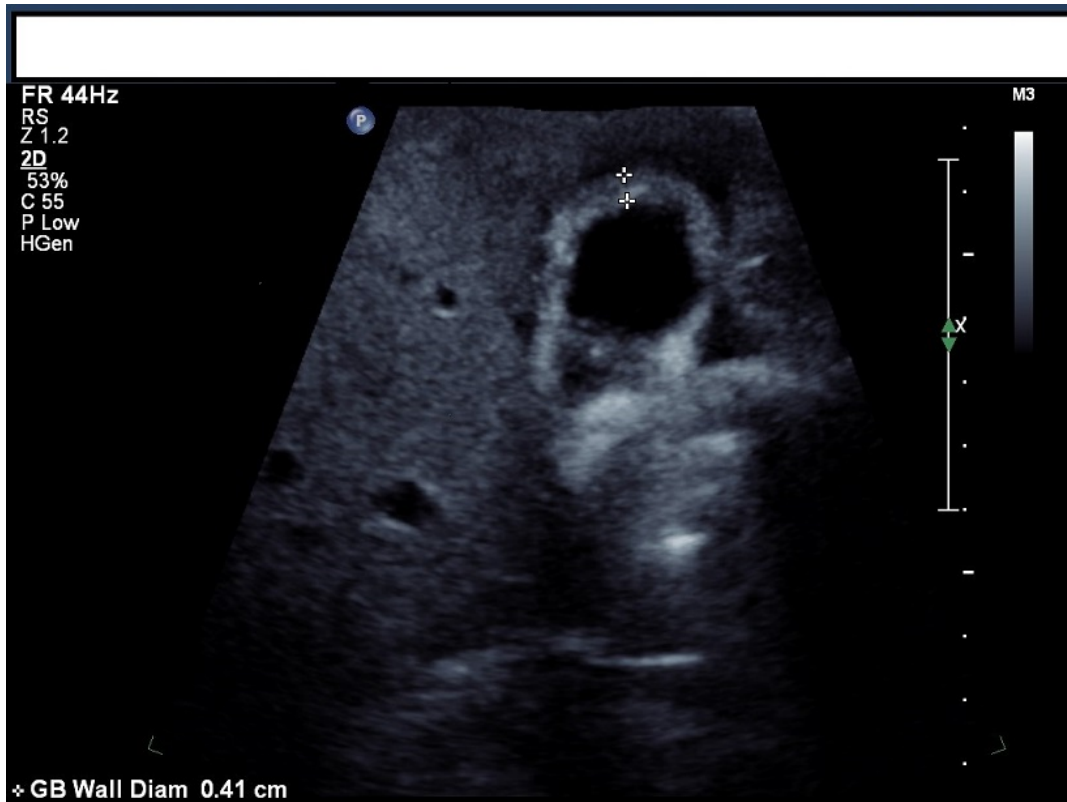

Figure 2: Ultrasound image of the gallbladder findings: thick walled gallbladder and cholelithiasis.

3. Discussion

Complications after colonoscopy are rare but can be life threatening. Intestinal perforation after colonoscopy has been reported at a rate of 0.3% [3]. Haemorrhage, another serious complication has been reported at rates of up to 0.6% [4]. A 2010 review of large prospective and retrospective studies and has an unweighted mortality rate of 0.03% after a colonoscopy [4]. Reported miscellaneous complications include splenic rupture, acute diverticulitis and acute appendicitis [3, 5]. Acute cholecystitis is generally a result of a combination of cystic duct obstruction secondary to cholelithiasis and irritation of the gallbladder mucosa [6, 7]. The pathophysiology of cholecystitis post colonoscopy is still to be explained [1]. About ten cases have been described in the literature [1]. These patients presented to hospital with symptoms 18-72 hours post colonoscopy. Several theories have been suggested as possible mechanism by which acute cholecystitis occurs after colonoscopy. The theories include bacterial translocation from colon to gallbladder, dehydration occurring after bowel preparation and physical movement of patient from side to side as part of colonoscopy could result in stones lodging into the gallbladder neck. However it is also worth considering whether these cases are pure coincidence. Colonoscopy as a screening and diagnostic procedure is common, so is cholelithiasis and therefore cholecystitis. In the case we present, the patient presented with lower abdominal pain. The radiological investigations showed evidence of cholecystitis without correlating clinical signs and symptoms which only developed 24 hours later. The lower abdominal pain was possibly unrelated to the developing cholecystitis as this pain later settled down with

analgesia. The patient went on to develop right upper quadrant pain during the admission and by the time of her operation 24 hours later the gallbladder was gangrenous. The culture from the cholecystectomy specimen grew E.Coli. This would suggest a possible translocation of bacteria from the gastrointestinal tract during colonoscopy.

4. Conclusion

Although rare, medical practitioners should be aware of the possibility of acute cholecystitis in patients presenting with right upper quadrant pain post colonoscopy. The phenomenon of cholecystitis post colonoscopy seems to be established. However more research is needed to explain the pathophysiology. The strength of this publication is limited by it being a case report.

5. Conflict of interest

No potential conflict of interest relevant to this article was reported.

- [1] M. M. Gorgan, I. Grigorescu, and D. L. Dumitrascu, "Acute Cholecystitis as a Complication After Colonoscopy: A Case Report and Literature Review," *European Journal of Case Reports in Internal Medicine*, vol. 3, 2016.
- [2] C. Fernández-Martínez, V. Plá-Martí, C. Flors-Alandí, and J. V. Roig-Vila, "Gangrenous cholecystitis after colonoscopy," *The American journal of gastroenterology*, vol. 97, p. 1572, 2002.
- [3] T. I. Park, S. Y. Lee, J. H. Lee, M. C. Kim, B. G. Kim, and D. H. Cha, "Acute cholecystitis after a colonoscopy," *Annals of coloproctology*, vol. 29, pp. 213-215, 2013.
- [4] C. W. Ko and J. A. Dominitz, "Complications of colonoscopy: magnitude and management," *Gastrointestinal endoscopy clinics of North America*, vol. 20, pp. 659-671, 2010.
- [5] A. Reumkens, E. J. Rondagh, C. M. Bakker, B. Winkens, A. A. Masclee, and S. Sanduleanu, "Post-colonoscopy complications: a systematic review, time trends, and meta-analysis of population-based studies," *The American journal of gastroenterology*, 2016.
- [6] S. F. Zakko, N. H. Afdhal, S. Chopra, and J. T. F. Chief, "Acute cholecystitis: Pathogenesis, clinical features, and diagnosis," <http://www.uptodate.com/contents/acute-cholecystitis-pathogenesis-clinical-features-and-diagnosis>, pp. 1-67, 2016.
- [7] J. Liu, Q. Yan, F. Luo, D. Shang, D. Wu, H. Zhang, et al., "Acute cholecystitis associated with infection of Enterobacteriaceae from gut microbiota," *Clinical Microbiology and Infection*, vol. 21, pp. 851.e1-851.e9, 9// 2015.