



International Journal of Sciences: Basic and Applied Research (IJSBAR)

ISSN 2307-4531
(Print & Online)

<http://gssrr.org/index.php?journal=JournalOfBasicAndApplied>



Role of Topical Cream Extract Garlic (*Allium sativum*) in Wound Healing Fibroblasts Judging from the Strain Wistar Rats with Acute Injury Models

Zaenal ^{a*}, Suryani As'ad ^b, Veni Hadju ^c, Agussalim Bukhari ^d

^a *Medical Science of Postgraduate Program, Faculty of Medicine, Hasanuddin University ; Faculty of Health Sciences, Islamic University Makassar*

^b *Nutrition Department, Medical Faculty, Hasanuddin University*

^c *Nutrition Study Program, Faculty of Public Health Hasanuddin University*

^d *Nutrition Department, Faculty of Medicine, Hasanuddin University*

^a *Email: zdaengbate@yahoo.com*

Abstract

Wound will cause problems if handled poorly, causing chronic wounds. Garlic (*Allium sativum*) is a typical plant of the tropics, including Indonesia, the tubers are often used in traditional medicine, among them to heal wound. This laboratory experimental study using randomized designs Post Test Control Group aims to determine the effect of the use of Topical Cream Extract garlic (*Allium sativum*) on wound healing in topical administration, with a view histopathologic consisting of fibroblasts.

* Corresponding author.

This study conducted using 4 laboratories are Biofarmaka Center activity of Research (PKP) Hasanuddin University to the process of making Cream Topical garlic extract (EBP10%), Laboratory Animal Medical Faculty of Hasanuddin University for maintenance and treatment of experimental animals, Laboratory of Histopathology Center for Veterinary Maros for manufacturing slide histopathology in September 2015 - February 2016. the study was conducted in 54 rats by making excision of the left and right back diameter of 8 mm by using punc byopsi. Then the mice were divided into 3 groups: negative control 0.9% NaCl, Oksitetracycline positive control group and a treatment group 3% Topical Cream EBP10%. The scar tissue of each group were observed microscopically on days 3, 7, and 14. The results showed wound healing treatment group tend to be better, seen in the mean value and standard deviation of the number of fibroblast cells EBP10% topical cream group on day 3 (1.0 ± 0.63), day 7 (1.5 ± 0.55) and day 14 (3.0 ± 0.63). Test results one way ANOVA fibroblast cell counts significantly different all groups based on the time of day 3 (p: 0.025) and day 14 (p: 0.000). Results of post hoc test showed no significant difference in the group EBP10% Topical Cream with negative control day 3 (p: 0.011), day 7 (P: 0.034) and (day 14 p: 0.000). In conclusion, Cream topical EBP 10%. tend to be useful in wound healing, and statistically significant.

Keywords: Garlic, fibroblasts, wound healing

1. Introduction

Wound healing is a complex process, involving interactions between cells and the matrix so that the process can walk. The natural wound healing process begins immediately after an injury and is a combination of regeneration and reparation processes, divided into three phases: the inflammatory phase, the proliferative phase and angiogenesis and the phase formation of connective tissue (tissue remodeling phase) [1].

The main purpose of handling the wound is healing fast achievement of the optimal functional outcome and cosmetics. Ideally, healing skin wounds should return to normal function [2, 3]. In 2005, in the United States there are 11.8 million cases of injuries treated at emergency departments with various causes. Luka on the skin, with a prevalence of approximately 10% among patients who are hospitalized, and 20% among patients bedrest-patient home care, is the second most frequently stated reason that causes people not to work, the high morbidity rate, causing high cost financial [3,4]. The high interest in research on medicinal plants due to the assumption that the medicinal plant is healthier than a synthetic product .Many herbs plantation available in nature or at home because in Indonesia garlic is an ingredient of the main ingredients are always encountered in the kitchen [4]. There are a variety of natural products that are empirically has been widely used as a traditional medicine to help the wound heal. One of the traditional medicines that can be used to treat wounds is garlic (*Allium sativum*) Garlic contains compounds essential chemical that is good for their body. Essential oils have antibacterial and antiseptic properties to prevent infection in the wound. Garlic has allicin active substances that have antibacterial and anti-inflammatory properties that can give effect to the recovery of the wound are a plant that has value. Garlic as antimicrobial, antiseptic, antibiotic, anti-inflammatory and analgesic [5,6].

Garlic contains compounds essential chemical that is very good for health. One is the essential oils that have antibacterial and antiseptic to prevent gangrene in patients with DM. Garlic has allicin active substances that have antibacterial and anti-inflammatory properties that can give effect to the wound recovery of ethanol extract of *Allium sativum* has a significant wound healing activity in rats. Flavonoids, saponins, alkaloids, and phenolics are known to have an active antibiotic principle [7]. Research conducted [8] that garlic extract in combination with honey accelerate wound healing process and the degree of sterility wound. Reference [4] conducted a study on the effect of the juice of garlic (*Allium sativum* L.) and honey (*Apis mellifera*) accelerates the time of wound closure in mice swiss Webster male models diabetes. The high interest in research on medicinal plants due to the assumption that medicinal plants are healthier than synthetic products. herbs are widely available in nature or at home because in Indonesia garlic is an ingredient of the main ingredients are always encountered in the kitchen [8].

Fibroblasts are the predominant cell in the third to fifth day after the injury and is able to trigger cell division baru. Pada proliferative phase, synthesis and activation of fibroblasts and macrophages by protein sektori trigger replacement fibrin matrix into a barn with the extracellular matrix of collagen as the main structure. This extracellular matrix remodeling will experience a continuous basis until the wound is healed. Fibroblasts are cells that synthesize extracellular matrix and collagen are instrumental in healing luka. Fibroblas serves to maintain the structural integrity of connective tissue by producing ekstraseluler. Fibroblas matrix derived from primitive mesenchymal-derived fibroblasts cytoplasm to the cell nucleus has a shape of an ellipse with one to two children cell nucleus. Fibroblasts produce collagen, glycosaminoglycans, elastin fibers and glycoproteins that form the extracellular matrix. Fibrosit as an inactive form will fibroblasts induced by macrophages into fibroblasts in wound healing. Fibroblasts accumulates in the injured area through angiogenesis between two to five days post-injury. The number of fibroblasts peaked about one week after the trauma and is the predominant cell in the first week phase of wound healing [1]. On histopathologic examination with hematoxylin-eosin staining, fibroblasts are generally grouped to form a line parallel to the cytoplasm reddish and density were measured with a micrometer graticule at 400x magnification [1,9].

2. Materials and Method

This study is an experimental research laboratory using the design Randomized Post Test Control Group using Wistar rats as subjects penelitian. Dengan number of samples is 54 samples of Wistar rats were divided into 3 major groups: control group negative, positive control group and a treatment group., More each group divided by 3 is based on the time dimension that is day 3, day 7, and day-to-14. For the third group was given a different experimental unit. The third group of general anesthetized using ketamine, then, modeling for the acute is done by way of excision of the left and right backs with a diameter of 8 mm by using punc byopsi. On the negative control group was given 0.9% NaCl, the positive control group Oksitetrasikline 3%, whereas in the treatment of Topical Cream of Garlic Extract 10% immediately after the injury created. The three groups then given topical preparations according to the group on the back as much as once every day until terminated, to be made histopathologic preparations of each rat on day 3, 7th, and 14th (respectively 6 mice). Histopathologic preparations for the two

groups on each day of observations by staining hematoxylin-eosin (HE) The number self-fibroblasts assessed quantitatively, (Table 1). The statistical analysis used statistical test is the test of one way ANOVA at 95% confidence level ($p < 0.05$). This study was approved by ethics of Health Research Ethics Committee of the Medical Faculty of Hasanuddin University in Makassar.

2.1 Making Model of Acute Sores

Anaesthetized rats by administration of inhaled ether with a dose of 0.5-1.0 cc are included in the box of anesthesia. After Wistar rat unconscious, the back area is cleaned with by using hair removal cream (Veet), then do disinfection with 0.5% chlorhexidine in 70% alcohol. Making models of acute injury through wound of diameter of 0.8 cm excision of skin bilateral dorsal area left and right to the examination of samples of TNF- α and VEGF on the one hand and on the other Fibroblasts. Excision is done using punch biopsies on epidermis up hypodermic / subcutaneous layer (wound degrees 2) (Li et al., 2011) .21

2.2 Extraction Procedure Garlic

In this study using Garlic Extract 10% by reference [7]. garlic sample cut into small pieces, the wind dried then blended .sample which has been finely added ethanol 70% then sonicated 1 hour later filtered. After the solvent was evaporated then the rest extract part in freeze drying to obtain extra ethanol white onion powder [7].

Topical Cream Making Procedures

1. Weighed material as follow [23]

Materials	Content (g)
Stearat Acid	1,5
Cethyl alcohol	2
Steril Alcohol	1,5
Gliserin	5
Propilen Glikol	10
Alfa Tokoferol	0,05
Metil Parabean	0,2

Propil Parabean	0,02
Novomer	1
Aquadest	To 100 gram

2. How to manufacture a cream base.

a. Ingredients such as acid stearate, cetyl alcohol and sterile alcohol and propyl paraben which had been weighed, melted until the temperature reaches 70 ° (Phase Oil) .Gliserin, propylene glikl, MP, and water heated to 70 ° (Phase Air)

b. The oil phase and the water phase was mixed at a temperature of 70o using a homogenizer while shaken after the temperature drops to about 40O added Novomer and alpha tocopherol is formed cream base

Measurement of cell count Fibroblasts

Excisional biopsy tissue fixation with paraffin blocks then stained with Van Gieson. The reading of the results number of fibroblasts using a microscope OLYMPUS BX series 41 is equipped with DP-70 digital camera and use software OLYSIA with magnification of 400 times of one dosage area observed 5. Then compared between the control group (K), the first treatment group (P1) and the treatment group II (P2). Data taken from readings in Histopathology Laboratory Center for Veterinary Maros. (Kiernan, 2008). [9]

3. Study Result

Fibroblasts and inflammatory cells which are building granulation tissue in this study is used as a parameter the formation of granulation tissue using staining HE.Survey done on the preparation day 3, the number of fibroblasts on average much more common in the treatment group compared with the control group .In both groups, fibroblasts in the new network is still rarely seen. On the 7th day preparations obtained fibroblast cell count average more in the treatment group compared with control group, Number of fibroblast cells on the 3rd day of the lowest found in the negative control group (0.17 ± 0.41) and highest in the group of garlic extract 10% (1.0 ± 0.63), on the 7th day fibroblast lowest quality found in the negative control group (0.83 ± 0.41) and highest in the group of garlic extract (1.5 ± 0.55). The amount of fibroblast cells on day 14, the lowest found in the negative control group (1.00 ± 0.00) and highest in the group of garlic extract 10% (3.0 ± 0.63) (Table 1).

The number of fibroblasts in the negative control group got nothing on day 3 (83.3%) and very little on day 7 (100.0%) and remained very little on day 14 (100.0%) . In the positive control group got very little on day 3 (83.3%) and remained very little on day 7 (66.7%) and less on day 14 (50.0%), the group garlic extract 10%. It was found very little on day 3 (83.3%) and very little on day 7 (50.0%) and was on day 14 (66.7%).

Table 1: Average picture Fibroblasts

Group	Mean	Std. Deviasi	Median	Min-Max
Day -3				
Negative control	0,17	0,41	0,0	0,0-1,0
Positive control	0,83	0,41	1,0	0,0-1,0
Garlic Extract 10%	1,0	0,63	1,0	0,0-2,0
Day -7				
Negative control	0,83	0,41	1,0	0,0-1,0
Positive control	1,33	0,52	1,0	1,0-2,0
Garlic Extract 10%	1,5	0,55	1,5	1,0-2,0
Day -14				
Negative control	1,00	0,0	1,0	1,0-1,0
Positive control	2,83	0,75	3,0	2,0-4,0
Garlic Ekstract 10%	3,0	0,63	3,0	2,0-4,0

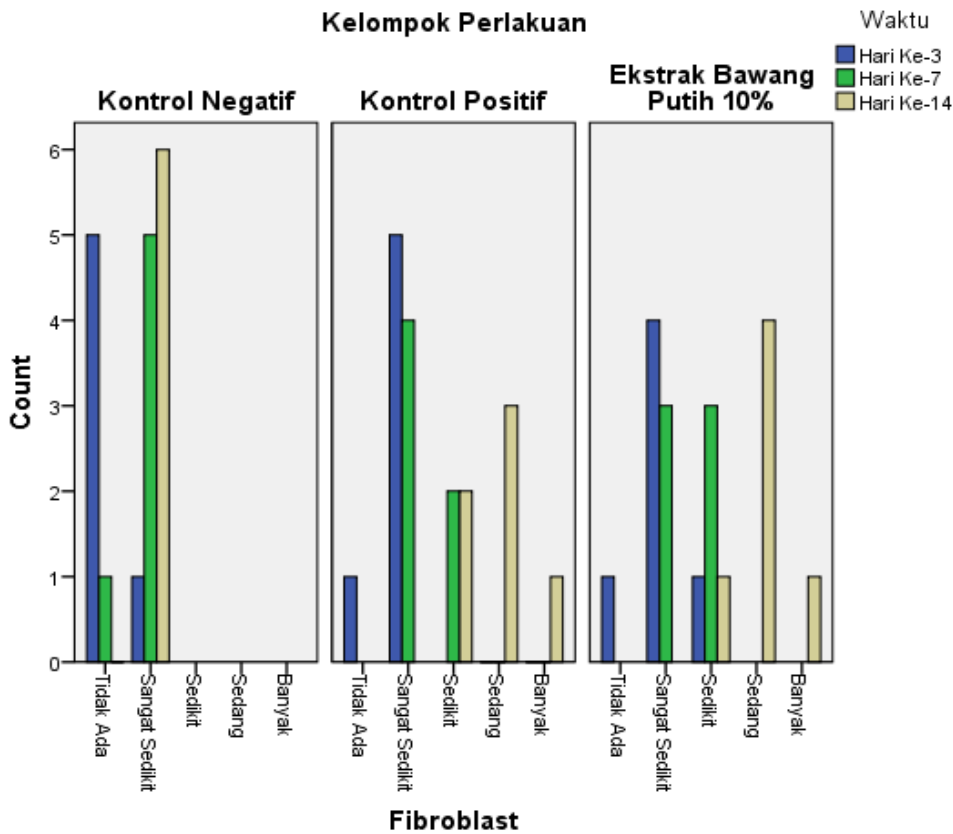


Figure 2: Fibroblast Based on the group III, VII day, and the day XIV.

Fibroblast analysis based group

1. Day III

Based on the statistical test one way anova, obtained p value: 0,025 which means there is a difference fibroblasts in all groups on day-III and then through Post hoc testing third day all known differences between groups are summarized as follow:

- a. Garlic 10% - K (-): significant ($p = 0.011$)
- b. Garlic 10% - K (+): not significant ($p = 0.568$)
- c. K (+) - K (-): significant ($p = 0.034$)

2. Day-VII

Based on the results one way ANOVA statistical test values obtained p : 0,008 which means there is no difference fibroblasts in all groups on day-VII and Beyond through Post hoc testing third day all known differences between groups are summarized as follow

- a. Garlic 10% - K (-): significant ($p = 0.034$)
- b. Garlic 10% - K (+): not significant ($p = 0.568$)
- c. K (+) - K (-): not significant ($p = 0.100$)

3. Day-XIV

Based on the results one way ANOVA statistical test values obtained p : 0,000 which means there is a difference fibroblasts in all groups on day XIV and then through Post hoc testing third day all known differences between groups are summarized as follow

- a. Garlic 10% - K (-): significant ($p = 0.000$)
- b. Garlic 10% - K (+): not significant ($p = 0.618$)
- c. K (+) - K (-): significant ($p = 0.000$)

Table 2: Fibroblast analysis based group

Group	Mean Difference	Post Hoc (p Value)	One Way Anova (p Value)
Day -III			
Garlic 10% - K (-)	0,833	0,011	0,025
Garlic 10% - K (+)	0,167	0,568	
K(+) - K (-)	0,667	0,034	
Day -VII			
Garlic 10% - K (-)	0,667	0,034	0,083

Garlic 10% - K (+)	0,167	0,568	
K(+)-K (-)	0,500	0,100	
Day -XIV			
Garlic 10% - K (-)	2,000	0,000	0,000
Garlic 10% - K (+)	0,167	0,618	
K(+)-K (-)	1,833	0,000	

Number of fibroblast cells on average much more common in the treatment group compared with the control group. In both groups, fibroblasts in the new network is still rarely seen. On the 7th day preparations obtained fibroblast cell count average more in treatment group compared with control group,

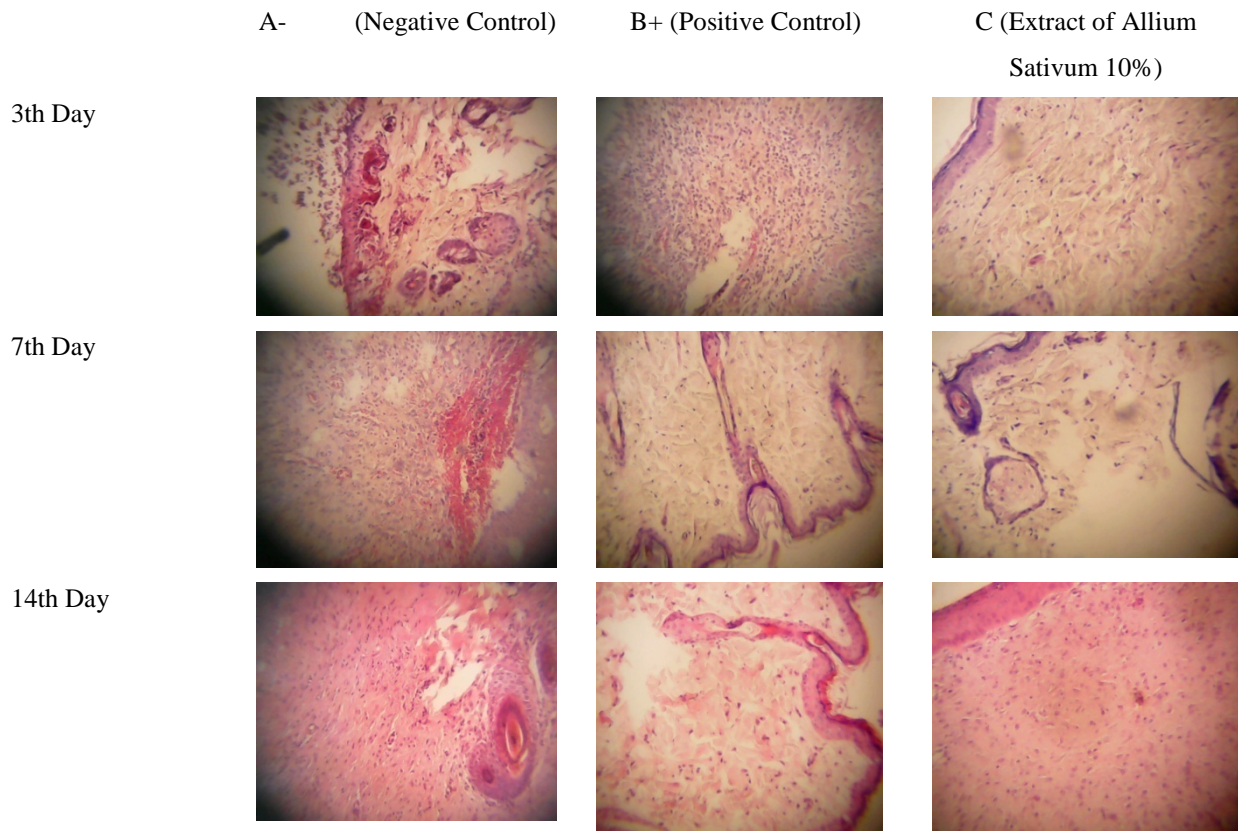


Figure 1: Overview of Histology Fibroblasts

4. Discussions

Wound healing is a process in which damaged tissue back as close as possible to the normal state [4]. While wound contraction is the shrinking of the wound area. It mainly depends on the network's ability to repair the damage, the

type of wound, the wound area, the state of healthy tissue general [10]. Re-epithelialization is the reformation of the epithelial lining of the surface of the wound so that the wound is closed, which is indicated by the migration of epithelial cells on the surface of the granulation tissue of the wound edges or its surround. Migration of healthy skin can occur a few hours after the injury occurs. Epithelial cells require viable tissue to the migration process, so if the wound within it must first be filled with granulation tissue injuries granule. Tissue composed by several types of cells are fibroblasts, macrophages and endothelial cells. Where the cells form an extracellular matrix, together with the new blood vessels into tissues forming the main component granule. Epithelial cells at the wound margins proliferate on day 2 or 3 after injury occurs to provide enough cells to migration process [11,12,13].

Barbul A. states that the fibroblasts first appeared significantly on day 3 and reached the peak on day 7. Peningkatan the number of fibroblasts in the wound area is a combination of the proliferation and migration. Fibroblasts derived from the undifferentiated mesenchymal cells, produce mucopolysaccharides, amino acids glycine and proline which is a basic ingredient of collagen fibers that will linkage wound edges. Growth is caused by a cytokine produced by macrophages and limfosit. Fibroblast also produce large amounts of collagen, collagen form triple chain glycoprotein, a key element wound extracellular matrix useful to form the strength of the network [14].

Phase proliferation also called fibroplasia phase because that stands out is the process of fibroblast proliferation. This phase lasts from the end of the inflammatory phase until approximately the end of the week to three. If no significant contamination or infection, the inflammatory phase short lasts. After successfully cleaned the wound of dead tissue and residual waste material, proliferasi. Fase proliferative phase begins characterized by the formation of granulation tissue in granulation wound. Tissue formed of three types of cells that play an important role in the formation of granulation tissue, the fibroblasts, macrophages, and endothelial cells. These cells form the extracellular matrix and new blood vessels, which histologically is a material for tissue granulasi [15]. Fibroblast first appeared significantly on day 3 and reached the peak on day 7. Peningkatan the number of fibroblasts in the wound area is a combination of the proliferation and migration. Fibroblasts derived from the undifferentiated mesenchymal cells, produce mucopolysaccharides, amino acids glycine and proline which is a basic ingredient of collagen fibers that will integrate the wound edges. Growth is caused by a cytokine produced by macrophages and limfosit. Fibroblast also produce large amounts of collagen, collagen form triple chain glycoprotein, a key element wound extracellular matrix useful to form the strength of the network parut. Kolagen first detected on day 3 after injury, increases until week 3. Kolagen continue to accumulate up to three months. References [15,16] also causes matrix fibronectin, hyaluronic acid and Glikos aminoglikan. On this phase, the fibers are formed and destroyed for the adjustment to the voltage on the injuries tend to constrict. Along with contractile properties miofibroblast, causing the pull on the wound edges. At the end of this phase, the tensile strength reaches 25% tissue injuries normal.

Fibroblasts are the histological features elliptical nucleus, large and light-colored, with fine chromatin and a clear nucleoli, the cytoplasm is filled with granuler. Fibroblast cytoplasmic reticulum is the cell that synthesizes the extracellular matrix and collagen are instrumental in healing luka. Fibroblas serves to maintain the structural integrity

connective tissue by producing ekstraseluler.Fibroblas matrix derived from mesenchymal derivatives primitif.Fibroblast own cytoplasm to the cell nucleus shape of an ellipse with one to two children cell nucleus. Fibroblasts produce collagen, glycosaminoglycans, elastin fibers and glycoproteins that form the extracellular matrix. Fibrosit as an inactive form will fibroblasts induced by macrophages into fibroblasts in wound healing. Fibroblast accumulates in the injured area through angiogenesis between two to seven days post-injury. The number of fibroblasts peaked about one week after the trauma and is the predominant cell in the first week [1].

Fibroblasts are building blocks of granulation tissue in this study is used as a parameter of granulation tissue formation using HE staining. The observations made in the preparation of the 3rd day, the number of fibroblast cells on average much more common in the treatment group compared with the control group. In both groups, fibroblasts in the new network is still rarely seen. On the 7th day preparations obtained fibroblast cell count average more in the treatment group compared with the group control Fibroblast quality on the 3rd highest in the group of garlic extract 10% (1.0 ± 0.63), on day 7 fibroblasts highest quality garlic extract group (1.5 ± 0.55). And the 14th highest in the group of onion extract putih10% (3.0 ± 0.63). Quality fibroblast groups garlic extract 10%. obtained very little on day 3 (83.3%) and very little on day 7 (50.0%) and was on day 14 (66.7%). Based on the statistical test of Kruskal-Wallis obtained the value of $p: 0,000$ which means that there are differences in fibroblasts in the negative control group based on time (day 3, day 7, day 14) Based on the Pearson correlation test obtained $r: 0.811$ directions positive correlation means fibroblast will increase from day to day in wound healing with the power of a strong correlation.

Fibroblasts derived from stem cells located in the lamina propria of the skin, then migrate and proliferate in the presence of cytokines and growth factors secreted by platelets and macrophages when injuries occur mainly transforming growth factor- β (TGF- β) and basic fibroblast growth factor (bFGF). BFGF secretion of macrophages and also of fibroblasts increased on days 7-14 post wounded in line with the number of fibroblasts increased during that period [17]. This study shows the treatment group the 3rd, 7th, and 14th, the number of fibroblasts were found more compared with the control group, and statistically there is a significant difference. Average number of fibroblasts in the treatment group more than control, especially in the proliferative phase, possibly from the effects of flavonoid compounds. From a research Middleton et.all 2000 known flavonoids also may increase receptor expression insulinlike growth factor-1 (IGF-1) as mediators of fibroblast proliferation and synthesis kolagen. beside, flavonoids are also capable of inhibiting degradative enzymes from neutrophils cells so that the treatment group no damage fibroblasts more [18]. Research Yulinda Primilisa proves the existence of water extract of allicin in garlic and the topical application of garlic extract water concentration of 10% effect on the number of fibroblasts in the wound healing process gingival rat strain Sprague dawley [19].

In the analysis of the nutritional content of 100 grams of garlic, there are water content, vitamin C, sulfur and other substances that are very positive function in the wound healing process. The content of substances had to drive the growth of cells that is effective and has the power of rejuvenation with a set of chemical processes in the body and heal inside and out. Contain high water will condition when moist wound and support the process of growth of new

tissue or granulation and epithelialization process network. Vitamin C also stimulates fibroblasts and histiocytes that can stimulate kapilarisasi [20].

Garlic also contains saltivine, scordinin, Gurwitch rays that can accelerate the growth of cells, the content of sulfur in garlic volatile when exposed to air, causing a hot response but can accelerate the drying process of the wound [5]. M. Salvi, Et.Al, found Garlic Oil. Its use in equines as promoter cicatrisation reported that hystopathological testified that granulation tissue began to appear on the 3th in wounds treated and that it was plentiful 12 days after operation [21]. Award, Topical Cream of Garlic Extract 10% to open the acute wound model showed satisfactory results. It can be seen from the greater volumes of fibroblasts formed, compared to the use of NaCl 0.9% and 3% ointment Oksitetraacycline .because Garlic Allicin has active substances that have antibacterial and anti-inflammatory properties that can give effect to the wound recovery, Garlic also has saltivine content, scordinin, Gurwitch rays that can accelerate the growth of cells, flavonoids, saponins and atsiri. Flavonoid oil can result in bacterial cell death that anti-inflammatory effect, affects re-epitelisasi so that the wound becomes faster cured. Saponin some bacterial. Essential oil of garlic bulbs have the ability some bacteria and antiseptic content of sulfur in garlic volatile when exposed to air, causing a hot response but can accelerate the wound curative process [22,23].

5. Conclusion

The number of fibroblasts in Wistar rat model of open wounds by administering more Topical Cream of Garlic Extract 10% compared to compared to the use of NaCl 0.9% and 3% ointment Oksitetraacycline

6. Suggestion

1. Need to do further research with a shorter time interval to learn more about the dynamics of wound healing, both clinically and histologically.
2. Further studies are needed to determine the strength of the linkage injuries such as stress or tensile strength tesile.
3. The studies should be done directly to people to determine their effectiveness.

References

- [1] Falanga V. (2004). The chronic wound: impaired healing and solutions in the context of wound bed preparation. *Blood Cells, Molecules, and Diseases*. p. 88–94.
- [2] Singer, A. J., Clark, R.A.F. 1999. Cutaneous Wound Healing. *The New England Journal Of medicine*, (on line). Vol.341, 738-746 (<http://www.ncbi.nlm.nih.gov/pubmed/10471461>. Diakses 17 Januari 2014
- [3] Falanga, V., Iwamoto,S. 2008. Wound repair mechanisms and practical considerations.fitspatrick's *Dermatology in General Medicine*. 7th edition.Mc. Hill : Amerika
- [4] Martinus Samuel 2012.Pengaruh air perasan bawang putih (*Allium sativum L.*) dan madu (*Apis mellifera*)

- terhadap waktu penutupan luka pada mencit swiss webter jantan model diabetes Jurnal Medika planta vol 2 no 1 Oktober 2012.
- [5] Syamsiah SI, Tajudin 2003. Khasiat dan Manfaat Bawang Putih. Raja Antibiotik Alami, Agromedia Pustaka: Jakarta..
- [6] Grieve M 2006. A Modern Herbal. (online) http://www.botanical.com/botanical/mgmh/g/garlic_o6.html. diakses tanggal 17 Januari 2016.
- [7] Mohammad Zuber, Voskula.Rajesh, Karra.Anusha,Chitteti.Rakesh Reddy,Ajimera.Tirupathi2013 wound healing activity of ethanolic of allium sativum alloxan induced diabetetic rats family International Journal Of Science Intervention today IJST.volume 2,issue 1
- [8] K.Sidik,AA.Mahmood and I Salmah 2006 Acceleration Of Wound Healing by Aquous of Allium Sativum in combination wih honey on cutaneus woud healing in Rats International Journal Of Molecular And Advance Sciences 2 (2): 231-235
- [9] Kiernan, J. A. 2008. Histological and Histochemical Methods: Theory andPractice 4th ed., p: 156-58.
- [10] Al-Henhena N MA, Al-magrami1 A, Nor Syuhada AB, Zahra AA, Summaya MD, Suzi MS, Salmah I. Histological study of wound healing potential by ethanol leaf extract of Strobilanthes crispus in rats. Journal of Medicinal Plants Research. 2011;5(16):3660–6.
- [11] Romo T and Pearson J.M.2005 Wound Healing, Skin.. Emedicine.com
- [12] Mulvaney M. and Harrington A. 1994 Chapter 7: Cutaneous trauma and its treatment. In, Textbook of Millitary Medicine: Millitary Dermatology.
- [13] Marcandetti M., Cohen A.J. Wound healing 2005: Healing and repair.. Emedicine.com
- [14] Barbul A. Wound Healing. In: F. Charles Brunicaardi M, FACS, editor. Schwartz's Manual Of Surgery. 8th ed. USA: McGraw-Hill; 2006. p. 165-8
- [15] Lisa Y. Hasibuan HS, Bisono. 2010.Luka. Buku-Ajar Ilmu Bedah. Ed.3 ed. Jakarta: EGC; 2010; 95 - 98.
- [16] Mendonça RJd. Angiogenesis in Wound Healing. In: Davies J, editor. Tissue Regeneration - From Basic Biology to Clinical Application. University Campus STeP Ri Slavka Krautzeka 83/A 51000 Rijeka, Croatia InTech; March, 2012. p. 93 - 108.
- [17] Suckow MA, Hodde JP, Wolters WR, HilesMC. 2005; Use of porcine renal capsule matrix as a full-thickness dermal wound-healing material in rats. J. Wound Care. 14: 137-140
- [18] Middleton E, Kandaswami C, TheoharidesCT. 2000. The effects of plant flavonoidson mammalian cells: implications forinflammation, heart disease, and cancer.Pharm Rev. 2000; 52: 673-751.
- [19] Yulinda Primilisa 2005 Pengaruh Aplikasi Ekstrak Air Bawang Putih (Allium Sativum Linn) Konsentrasi 10% Secara Topikal Terhadap Jumlah Fibroblas (Kajian Histologis Pada Proses Penyembuhan Luka Gingiva Tikus Putih Sprague Dawley) [Http://Bapendik.Unsoed.Ac.Id/Index.Php?R=Artikelilmiah/View&Id=4201](http://Bapendik.Unsoed.Ac.Id/Index.Php?R=Artikelilmiah/View&Id=4201)
- [20] Waluyo, Bambang 2001. Bawang Putih “Sang Penguat Tubuh”.<http://www.kbi.gemari.or.id/beritadetil.php.html>. diakses tanggal 7Maret 2016.

- [21] M. Salve, Daniela Zubeldia, J. Sereno, Patricia Bertone, R. Cocco, J. Rotondo, it Audap Soubie. Garlic Oil. Its use in equines as a promoter of cicatrisation
- [22] Li, K, Diao, Y, Zhang, H, Wang, S, Zahang Z, Yu B, Huang, S & Yang, H 2011, tannin Extract from immature Fruits Of Terminalia chebula Fructus Rets . Promote Cutaneous Wound healing in Rats, *BMC Complementary and Alterantive Medicine*, Vol 11, pp 1-8
- [23] Wiren K, Fritiof H, Sjoqvist C, Loden M. 2009; Enhancement of bioavailability by lowering of fat content in topical formulations. *Br J Dermatol.* 160: 552-6