



---

## **Spontaneous Chylothorax Secondary to Kyphoscoliosis: A Case Report**

Yasser El-Ghoneimy<sup>a</sup>, Mohammed AlDossary<sup>b\*</sup>, Hamad AlMakinzy<sup>c</sup>, Tlal  
AlSofyani<sup>d</sup>, Noura AlNafea<sup>e</sup>

<sup>a</sup> Associate Professor and Cardiothoracic Surgeon, University of Dammam, King Fahd Hospital of the  
University, Al-Khobar P.O. Box 2208, Saudi Arabia.

<sup>b,c,d,e</sup> Medical intern, University of Dammam, King Fahd Hospital of the University, Al-Khobar, Saudi Arabia.

<sup>a</sup> Email: yfarag@ud.edu.sa

<sup>b</sup> Email: Dr.hamodzzz@gmail.com

<sup>c</sup> Email: h-makenzi@hotmail.com

<sup>d</sup> Email: o.d\_@hotmail.com

<sup>e</sup> Email: Noura.alnafea91@gmail.com

### **Abstract**

chylothorax refers to the accumulation of fluid in the pleural cavity containing chylomicrons due to disruption of the thoracic duct. Currently, the most common causes of chylothorax are surgery and tumors; however, spontaneous chylothorax is still rare. Here we report an unusual presentation of spontaneous chylothorax secondary to severe kyphoscoliosis in a 9-year-old girl who presented with a symptomatic left chylothorax.

**Keywords:** Case reports; kyphoscoliosis; spontaneous chylothorax.

---

\* Corresponding author.

## **1. Introduction**

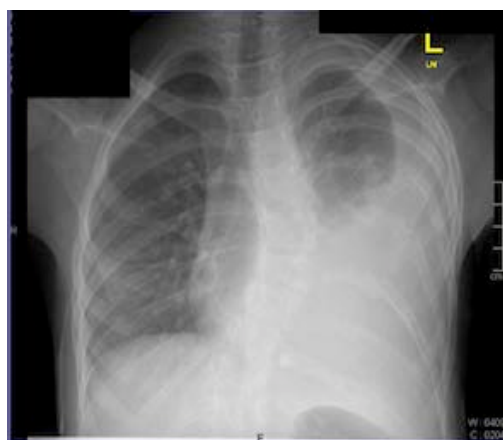
Chylothorax is a rare condition that refers to the accumulation of fluid in the pleural cavity containing chylomicrons due to disruption of the thoracic duct [1,7,9].

The incidence of chylothorax is rare in most children [11]. Clinically, chylothorax manifests by dyspnea, cough, and chest discomfort [4]. Patients can be hemodynamically unstable (e.g., hypotension, cyanosis, and severe respiratory distress) if a large volume of fluid accumulates in the pleural cavity [6,11]. Causes of chylothorax can be congenital, traumatic (iatrogenic or noniatrogenic), neoplastic, spontaneous, and miscellaneous [4,11]. Here we present a unique case with an interesting manifestation of chylothorax that was secondary to kyphoscoliosis.

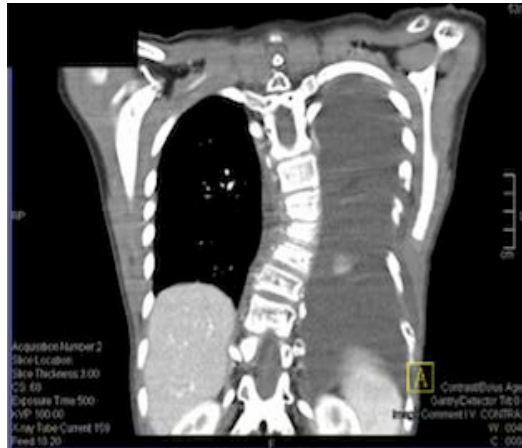## **2. Case Report**

A 9-year-old Saudi girl was known to have severe kyphoscoliosis, and she was brought to the emergency room by her mother due to severe dyspnea associated with chest pain and palpitation for 4 days. There was no history of trauma and no previous surgical intervention. On clinical examination, the patient was stable, and she was not in respiratory distress with an oxygen saturation of 98% on room air. There was diminished chest expansion with stony dullness on percussion in the left side of the thickest rib. Air entry was absent on the left side. Chest radiography showed homogeneous opacity on the left side with a mediastinal shift to the right side, indicating a massive left pleural effusion (Fig.1). Computed tomography (CT) scan confirmed the presence of free fluid in the left pleural cavity and a collapsed lung (Fig. 2 a,b). Also, there was severe kyphoscoliosis in the thoracic vertebrae, thus video-assisted thoracoscopic surgery was planned for diagnosis and drainage of the fluid.

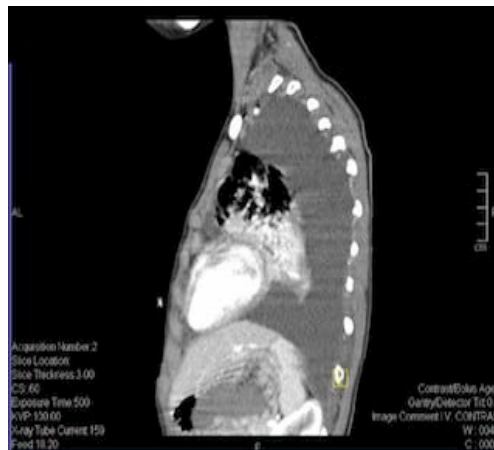The fluid was milky in color, and it had no smell or loculations. A large amount of fluid (750 mL) was drained and sent for chemical and cytological examination. Chemical analysis showed the following data: triglyceride level, 2,855 mg/dL; cholesterol level, 357 mg/dL; lactate dehydrogenase level, 109 IU/L; and fluid albumin, 2.1 g/dL, which confirmed the diagnosis of chylothorax.



**Figure 1:** Chest radiography showed homogeneous opacity on the left side with a mediastinal shift to the right side, indicating a massive left pleural effusion.



**Figure 2a:** Computed tomography (CT) scan of the chest PA view, confirmed the presence of free fluid in the left pleural cavity and a collapsed lung.

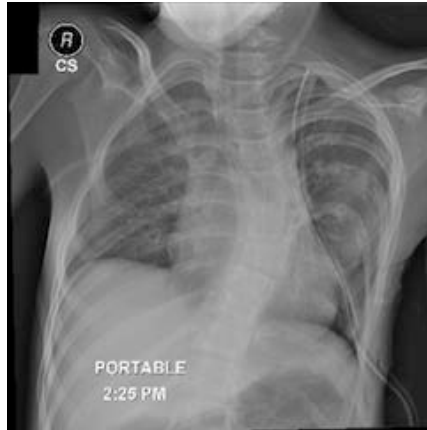

**Figure 2b:** Computed tomography (CT) scan of the chest, left lateral view, confirmed the presence of free fluid in the left pleural cavity and a collapsed lung.

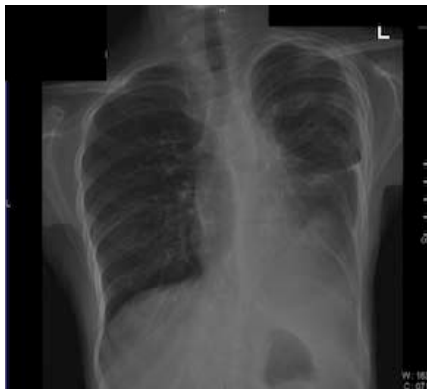Conservative management was performed, which included tube drainage (Fig. 3), diet control, and restriction of fat in the patient's diet for 2 wk until the drainage became minimal and the chest tube was removed (Fig. 4). The patient was discharged home in a stable condition.

### 3. Discussion

Chylothorax is a relatively uncommon cause of pleural effusion. Our patient's presentation of chylothorax was likely secondary to kyphoscoliosis. Chylothorax is diagnosed by measuring the triglyceride and cholesterol levels of pleural fluid, and if the triglyceride level is above 110 mg/dL and the ratio of the pleural fluid to serum cholesterol is  $<1.0$ , the diagnosis of chylothorax is confirmed [4]. Additionally, imaging studies such as CT scans can be useful for detecting small amounts of contrast material in the pleural space [11].



**Figure 3:** Chest radiography showed chest tube inserted in the left side of the chest for drainage.



**Figure 4:** Chest radiography showed improvement in the left side of the chest, drainage became minimal and the chest tube was removed.

### 3.1 Management of chylothorax

Generally, the success rate of conservative treatment ranges from 20–80% [8], with drainage output rates of >1,000 mL/day. The standard approach for treating chylothorax is draining the pleural fluid by placing an indwelling chest tube [11].

The aim of pharmacotherapy treatment with a somatostatin analogue is to decrease blood flow to the portal, hepatic, and splanchnic circulations, leading to a decrease in lymph flow through the thoracic duct [3].

If conservative treatment fails, surgical intervention is considered. Pleurodesis, thoracic duct ligation, and a pleuro-peritoneal shunt are reported treatments for chylothorax [5]. Thoracic duct ligation can be performed by thoracoscopic intervention or thoracotomy [7,10]. Thoracic duct ligation is successful in 90% of patients when performed above the right hemi-diaphragm [7].

### 4. Timing of surgical interventi

The daily drainage output from the chest tube is usually the most important indicator of the patient's chance of

success with conservative therapy. In a healthy adult, daily drainage from the thoracic duct is 1.5–4 L of chyle; however, the amount of drainage varies significantly among patients, and in general, a volume of  $\geq 1,000$  mL/day defines a high-output leak [2,12,13]. Early recommendations suggest a 2-wk course of conservative treatment before surgical intervention [12,14].

## **5. Conclusions**

In cases of spontaneous chylothorax, medical treatment should be started first, with the aim to close the lymph leak by decreasing the flow of lymph. If medical treatment fails, the next option to consider is surgical intervention.

## **References**

- [1] Akpınar V, Duran FY, Duman E, Özkalkanlı MY, Duran Ö, Horsanlı B. “Bilateral chylothorax after falling from height.” *Case Reports in Surgery*, vol. 2014, pp. 618708, Jun. 2014.
- [2] Browse NL, Allen DR, Wilson NM. “Management of chylothorax.” *British Journal of Surgery*, vol. 84, pp. 1711-1716, Dec. 1997.
- [3] Caverly L, Rausch CM, da Cruz E, Kaufman J. “Octreotide treatment of chylothorax in pediatric patients following cardiothoracic surgery.” *Congenital Heart Disease*, vol. 5, pp. 573-578, Nov-Dec. 2010.
- [4] Tutor JD. “Chylothorax in infants and children.” *Pediatrics*, vol. 133, pp. 722-733, Apr. 2014.
- [5] Engum SA, Rescorla FJ, West KW, Scherer LR 3rd, Grosfeld JL. “The use of pleuroperitoneal shunts in the management of persistent chylothorax in infants.” *Journal of Pediatric Surgery*, vol. 34, pp. 286-290, Feb. 1999.
- [6] Light RW. “Chylothorax and pseudochylothorax,” in *Pleural Diseases*, 6th ed., Pennsylvania: Wolters KluwerLippincott Williams and Wilkins, 2013, pp.
- [7] McGrath EE, Blades Z, Anderson PB. “Chylothorax: aetiology, diagnosis and therapeutic options.” *Respiratory Medicine*, vol. 104, pp. 1-8, Jan. 2010.
- [8] Schild HH, Strassburg CP, Welz A, Kalff J. “Treatment options in patients with chylothorax.” *Deutsches Ärzteblatt International*, vol. 110, pp. 819-826, Nov. 2013.
- [9] Seitelman E, Arellano JJ, Takabe K, Barrett L, Faust G, George Angus LD. “Chylothorax after blunt trauma.” *Journal of Thoracic Disease*, vol. 4, pp. 327-330, Jun. 2012.
- [10] Slater BJ, Rothenberg SS. “Thoracoscopic thoracic duct ligation for congenital and acquired disease.” *Journal of Laparoendoscopic & Advanced Surgical Techniques*, vol. 25, pp. 605-607, Jul. 2015.
- [11] Soto-Martinez M, Massie J. “Chylothorax: diagnosis and management in children.” *Paediatric Respiratory*

Review, vol. 10, pp. 199-207, Dec. 2009.

[12] Stager V, Le L, Wood RE. "Postoperative chylothorax successfully treated using conservative strategies." Proceedings (Baylor University Medical Center), vol. 23, pp. 134-138, Apr. 2010.

[13] Wemyss-Holden SA, Launois B, Maddern GJ. "Management of thoracic duct injuries after oesophagectomy." British Journal of Surgery, vol. 88, pp. 1442-1448, Nov. 2001.

[14] Williams KR, Burford TH. "The management of chylothorax." Annals of Surgery, vol. 160, pp. 131-140, Jul. 1964.