



---

# **The Use of the Nonionised Electromagnetic Waves’ Enhanced Local Cellular Injection for Treatment of Osteoarthritis: Case Report**

Dr. Bassem Darwish\*

*M.D., Orthopedic consultant & head of the orthopedic department, Al-Rafie hospital, Holly Makkah, postal  
code: 21955, Saudi Arabia*

## **Abstract**

Osteoarthritis is thought to be the most prevalent chronic joint disease presenting with joint pain, tenderness, stiffness, locking, and sometimes an effusion. Diagnosis is confirmed by x-ray. Treatment involves a combination of exercise, lifestyle modification, analgesics, steroids, glucosamine, and finally arthrodesis and joint replacement surgery. A 50 years old female with moderate osteoarthritis that did not respond to traditional medical treatment was treated by nonionised electromagnetic waves’ enhanced local cellular injection where 120 ml of blood was subjected to series of centrifugation in speeds ranging from (4000-12000) round per minute then the cells was exposed to nonionised electromagnetic waves in a spectrum ranging from (350-850) nanometer and for duration ranging from (60-180) seconds in complete aseptic procedures. Each knee was injected with 10 ml of cells in aseptic precaution and under umbrella of antibiotic. Improvement of pain was recorded from the 4<sup>th</sup> post injection day and x-ray after 1 year showed evidence of cartilage regeneration

**Keywords:** Osteoarthritis; knee; cellular; injection; electromagnetic waves; enhanced; regeneration; pain.

## **1. Introduction**

Osteoarthritis is thought to be the most prevalent chronic joint disease [1]. Osteoarthritis is believed to be caused by mechanical stress on the joint and low grade inflammatory processes [2].

---

\* Corresponding author.

E-mail address: [author@institute.xxx](mailto:author@institute.xxx) .

The incidence of osteoarthritis is rising because of the ageing population and the epidemic of obesity [1].

The main symptom is pain, causing loss of ability and often stiffness. "Pain" is generally described as a sharp ache or a burning sensation in the associated muscles and tendons.

OA can cause a crackling noise (called "crepitus") when the affected joint is moved or touched and people may experience muscle spasms and contractions in the tendons. Occasionally, the joints may also be filled with fluid. Some people report increased pain associated with cold temperature, high humidity, and/or a drop in barometric pressure, but studies have had mixed results [3] & [1].

Osteoarthritis commonly affects the hands, feet, spine, and the large weight bearing joints, such as the hips and knees. Symptoms may include joint pain, tenderness, stiffness, locking, and sometimes an effusion. A variety of causes; hereditary, developmental, metabolic, and mechanical deficits may initiate processes resulting in destruction of cartilage. When bone surfaces become less well protected by cartilage, bone may be exposed and damaged. As a result of decreased movement secondary to pain, ligaments may become more lax and regional muscles become atrophied [4].

X-rays may confirm the diagnosis. The typical changes seen on X-ray include: joint space narrowing, subchondral sclerosis, subchondral cyst formation, and osteophytes. Plain films may not correlate with the findings on physical examination or with the degree of pain. Clinicians recognise that the diagnosis of osteoarthritis is established late in the disease process, may be too late to expect much help from disease-modifying drugs. Treatment generally involves a combination of exercise, lifestyle modification, analgesics, oral & intra-articular steroids, oral glucosamine & intra-articular hyaluronic acid. If pain becomes debilitating, arthrodesis & joint replacement surgery may be used to improve the quality of life [1].

## **2. Material & Method**

50 years old, non smoker, female patient, was suffering from moderate osteoarthritis of both knee joints, with pain in both knees, increasing with climbing up stairs, down stairs, with kneeling (she used to pray in the sitting position) and she was unable to sit in the squatting position.

Examination revealed, tenderness over the patella and joint line, crepitus over the patella with active and passive motion, full range of knee motion with tenderness on full flexion, stable knees, no evidence of knee joint effusion

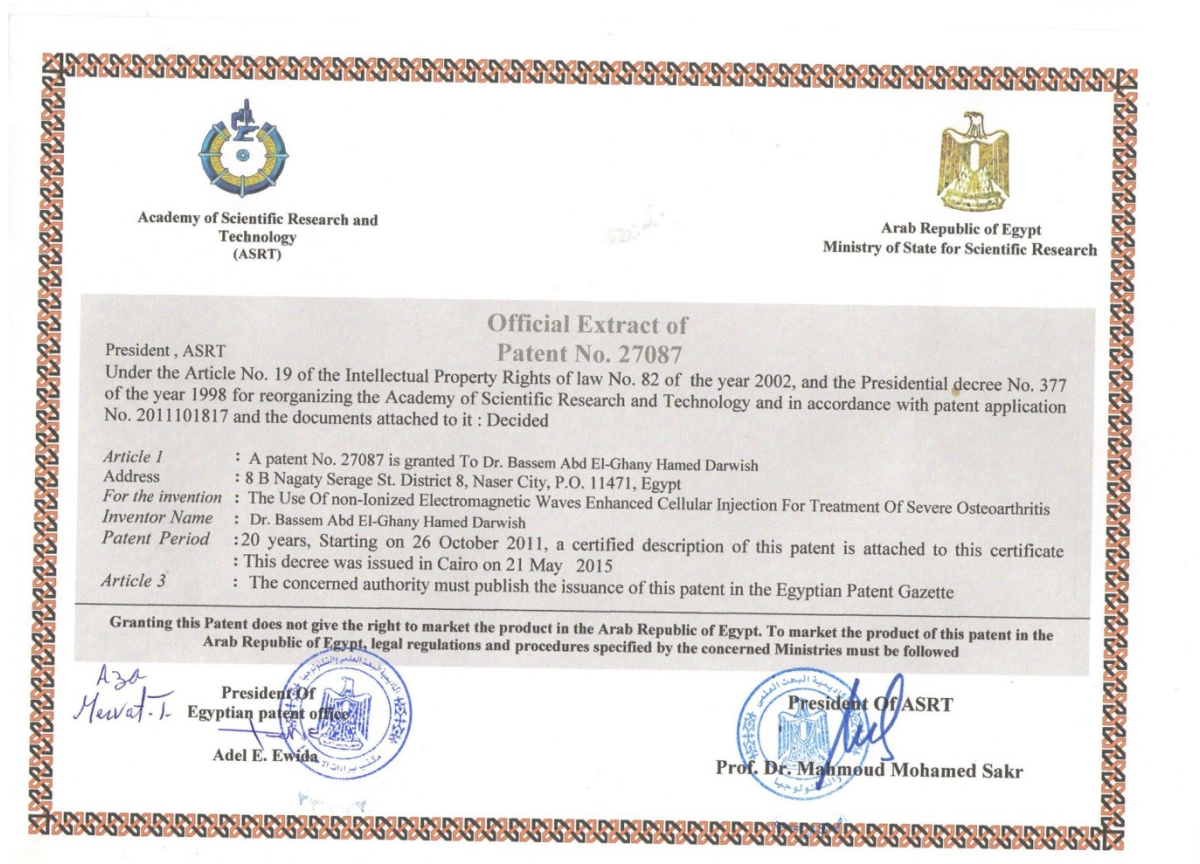Plain x-ray of both knees, antero-posterior erect & lateral views showed sharp tibial spine, spurring of the upper pole of the patella, & narrow joint space more in the medial joint compartment.

The patient was taking non-steroidal anti-inflammatory drugs, oral steroids, local intra-articular steroids injection, oral glucosamine with temporary improvement and recurrence of pain once medication was stopped.

C-reactive protein was done to the patient before injection to exclude the presence of any infection in the body.

## 2.2 Description of the technique:-

According to the procedure described in patent number 27087 EPO [5] & [6]. See Figure 1.



**Figure 1:** official extract of patent 27087

Nonionised electromagnetic waves' enhanced local cellular injection was done to the patient where 120 ml blood was aspirated from the superficial vein after adding EDTA anticoagulant solution to prevent blood coagulation, the blood sample is subjected to series of centrifugation processes in speeds ranging from 4000-12000 round per minutes then the separated cells are exposed to nonionised electromagnetic waves (spectrum ranging from 350-850 nanometer) and for duration ranging from 60-180 seconds after which the syringes are covered with opaque adhesive cover to isolate the cells from light Intra-articular injection was performed after disinfection of the area from the mid thigh to the mid leg with ethyl alcohol spray 95%. Injection was done in the lateral joint compartment 1cm lateral to patellar tendon & 1 cm above the upper surface of the tibia. 10 ml was injected in each knee.

After the injection the knee is flexed & extended 3 successive times to ensure proper distribution of cells in all the knee compartments then the injection site is covered with sterile adhesive which is kept dry for 4 days.

The patient experience severe agonizing pain during the injection procedure which decreases in intensity within the next 20 minutes where it becomes bearable.

Oral 1 gm amoxicillin/clavulanic acid was given to the patient every 12 hours for 4 days and acetaminophen two 500 mg tab every 6 hours.

The patient was instructed to measure her body temperature every 12 hrs by a thermometer and was instructed to contact the doctor if she noticed any elevation in temperature.

After 4 days the patient had removed the sterile adhesive , worn hinged knee brace and started weight bearing. Hinged knee braces were used during the day time and removed before sleep for 9 months after injection.

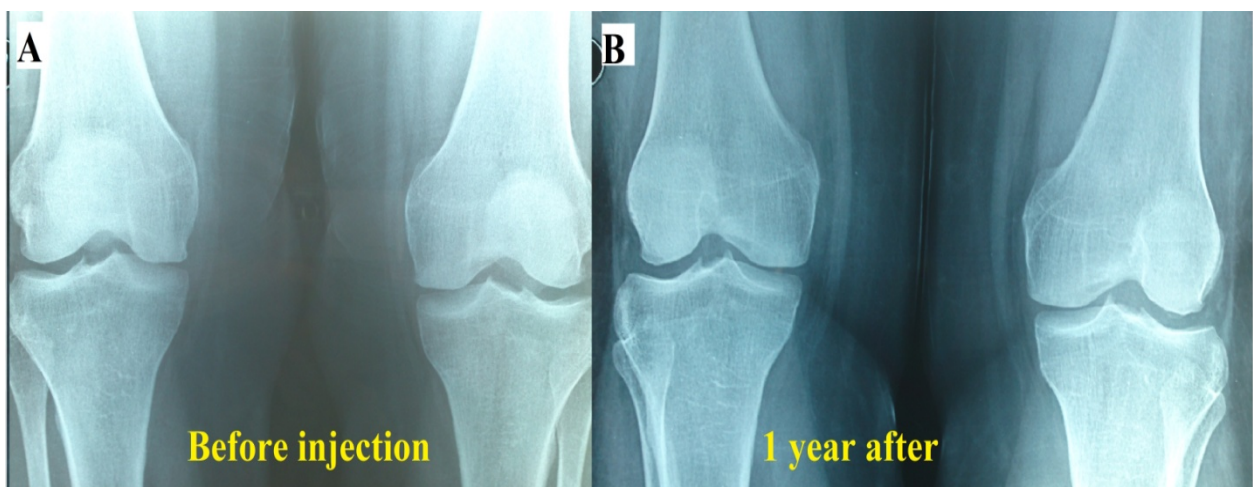
The patient started to feel improvement of pain from the 4<sup>th</sup> day after injection. She stopped all the medications and experienced improvement in pain which was continuous in the 1 year follow up post injection period and erect x-ray of the both knees showed increase in the joint height (distance between the upper surface of the tibial condyles & lower surface of the femoral condyles) which was more evident in the medial joint compartment.

The only complication of such procedure is septic arthritis and the prophylactic measures against such complication is the aseptic preparation of the cells, wide disinfection of the injection area, prophylactic antibiotic started immediately before or immediately after injection.

### 3. Results and Discussion

Articular cartilage possesses poor natural healing mechanisms, & no drug used for osteoarthritis is known to promote regeneration of the hyaline cartilage. All medication used for alleviation of symptom & not to heal the underlying histopathological condition.

Nonionised electromagnetic waves' enhanced local cellular injection improves the symptoms of osteoarthritis particularly pain which is improved starting from the 4<sup>th</sup> post injection day in addition to evidence of hyaline cartilage regeneration denoted from the increased joint height in the 1 year post injection x-ray.(Figure 2)



**Figure 2:** Antero-posterior erect x-ray view of both knees. A: before injection; B: 1 year after nonionised electromagnetic waves' enhanced local cellular injection

#### 4. Conclusion

Limited good result of evidence showed that repeated Nonionised electromagnetic waves' enhanced local cellular injections improve osteoarthritis both clinically and radiologically. Case series study is recommended to augment the evidence of the effect of this type of treatment

#### Funds

No funds, sponsorship or financial support to be disclosed.

#### Acknowledgment

I would like to express appreciation to prof. Mahmoud Al-Kady, Prof. of orthopedic surgery in Al-Azhar University in Cairo.

#### References

- [1] Johannes Bijlsma, Francis Berenbaum, Floris Lafeber: "Osteoarthritis: an update with relevance for clinical practice." *The Lancet*, vol. 377, pp 2115–2126, 2011.
- [2] Berenbaum F: "Osteoarthritis as an inflammatory disease (osteoarthritis is not osteoarthrosis)". *Osteoarthritis and Cartilage*, vol. 21 (1),pp. 16–21, 2013.
- [3] de Figueiredo EC, Figueiredo GC, Dantas RT: "Influência de elementos meteorológicos na dor de pacientes com osteoartrite: Revisão da literature, Influence of meteorological elements on osteoarthritis pain: a review of the literature". *Rev Bras Reumatol* (in Portuguese) vol. 51 (6), pp 622–628, 2011
- [4] Manek NJ, Lane NE: "Osteoarthritis: current concepts in diagnosis and management." *Am Fam Physician*, vol. 61(6), pp 1795–1804, 2000.
- [5] Bassem Darwish "The use of the nonionised electromagnetic waves'enhanced cellular injection for treatment of severe osteoarthritis." Egypt Patent 27087, Oct. 26, 2011.
- [6] Nayera Abdelmoaty, E. Alattar, Khaled Ahmad, Yosra Ibrahim, Bassem Darwish: "Regenerative Power of Autologous Peripheral Blood Stem Cell Injection in Knee Osteoarthritis by A NON Invasive Approach - MRI Study-." *Ann Rheum Dis*, vol.73(2),1066, 2014