



Tissue Expression of Glutathione S- Transferase P1 and Matrix Metalloproteinase-9 Tissue in Egyptian Patients with Barrett Esophagus and Esophageal Adeno-carcinoma

Naglaa Zayed^a, Magda Morad^b, Ehab Elsayed^c, Wafaa Ezzat^{d*}, Sameh Labib^e

^{a,e} Endemic Medicine and Hepatology Department, Gastrointestinal Endoscopy Unit, Faculty of Medicine, Cairo University, Cairo, 11562, Egypt

^{b,e} Pathology Department, National Cancer Institute, Cairo University, Cairo, 11712, Egypt

^{a,c,d} Internal Medicine Department, National research Center, Cairo, 12311, Egypt.

^aEmail: naglaazayed@yahoo.com

^bEmail: drmagdamourad@hotmail.com

^dEmail: wafaa_3t@yahoo.com

^eEmail: labib@link.net

Abstract

The identification of biomarkers in the presence of Barrett's esophagus (BE) and esophageal adenocarcinoma (EAC) has the potential to improve patient outcomes through earlier diagnosis and treatment. AIM Evaluate the esophageal tissue expression of glutathione S-transferaseP1 (GSTP1) and matrix metalloproteinase-9 (MMP-9) in patients with reflux esophagitis, BE and EAC. Tissue expression of both GSTP1 and MMP-9 were analyzed in 120 paraffin-embedded esophageal samples by immune histochemistry obtained from 60 Egyptian patients; gastro-esophageal reflux disease(GERD)(n= 15), BE (n= 15), EAC (n= 15) in addition to a control group with normal gross and histologic esophageal tissue (n= 15). Immunostaining was determined semi-qualitatively in all groups. Normal esophageal mucosa demonstrated the lowest MMP-9 and highest GSTP1 tissue expression compared to all other groups; $p < 0.001$. In contrast, the tissue expression of MMP-9 was significantly higher and GSTP1 was significantly lower in EAC and dysplastic BE than other groups; p value < 0.001 .

* Corresponding author.

E-mail address: wafaa_3t@yahoo.com.

Dysplastic BE demonstrated a significant higher MMP-9; $p < 0.04$ and lower GSTP1 tissue expression; $p < 0.003$ compared to patients with non-dysplastic BE and GERD, however, no major changes were observed between non-dysplastic BE and GERD. The significant down-regulation of MMP-9 was coupled by up-regulation of GSTP1 expression along the whole spectrum of the disease, p value < 0.001 . The imbalance between tissue GSTP1 and MMP-9 in BE and EAC could be considered as potential markers that might be useful to identify patients at higher risk for progression to cancer.

Keywords: Glutathione S-transferase; Matrix metalloproteinase-9; Barrett's Esophagus; Adenocarcinoma; Dysplasia, Egypt.

1. Introduction

Esophageal adenocarcinoma (EAC) develop almost exclusively in the distal third of the esophagus, under the chronically damaging effect of gastro-esophageal reflux disease (GERD) [1,2]. Barrett's esophagus (BE); a condition in which the normal squamous epithelium of the distal esophagus is replaced by a metaplastic, intestinal columnar-like epithelium is regarded as precancerous lesion. However, in a small minority of individuals; 0.5-2.0% per year [3]; malignant progression follows a multistage process involving well-characterized histopathologic changes from intestinal metaplasia-low grade and high grade dysplasia-esophageal adenocarcinoma [1,2,4].

Effective surveillance techniques can be accomplished by endoscopic sampling at regular intervals particularly those with high probability of harboring dysplasia [5]. However, sampling error, the intra- and inter-observer variation in the scoring of dysplasia and the relatively low prognostic ability represent significant limitations for histopathology [6]. Thus, the recognition of a panel of biomarkers obtained from genomic profiling of BE and EAC patients may direct the endoscopic surveillance intervals among high risk patients [7].

In the multi-step process of carcinogenesis, tumor invasion step requires the degradation of the extracellular matrix (ECM) and connective tissue surrounding the tumor by matrix metallo-proteinase (MMPs) [8]. In addition, oxidative DNA damage and the subsequent increase risk of cancer susceptibility is associated with altered expression and activity genetic polymorphisms in glutathione S-transferase (GST). MMPs are associated with various physiological and pathological processes such as morphogenesis, angiogenesis, tissue repair, metastasis [9] as well as tumor aggressiveness and prognosis in human esophageal carcinomas. On the other hand, an inverse correlation was demonstrated between GST enzyme activity and tumor incidence in the gastrointestinal tract. The down-regulation of GST expression could be an early event in the development of BE [10] and the lack of GST P1 expression is associated with poor prognosis [11].

The aim of the current study is to investigate the tissue expression of glutathione S-transferase P1 (GSTP1) and matrix metalloproteinase-9 (MMP-9) in the development and progression of reflux esophagitis-Barrett's esophagus-dysplasia-adenocarcinoma sequence in the esophagus.

2. Patients and Methods

2.1 Study population

Endoscopic specimens from 45 symptomatic patients who had undergone upper gastrointestinal endoscopy at Gastrointestinal Endoscopy Unit, Kasr El-Aini Hospital, Faculty of Medicine, Cairo University were included in our study. Patients' symptoms included dyspepsia, heartburn, dysphagia, eructation, and epigastric pain. Informed consent was obtained from all patients and a local ethical approval from the institution had been obtained.

Furthermore, archival formalin-fixed, paraffin-embedded tissue biopsies obtained from patients with EAC(n=15) were retrieved from Pathology Department, National Cancer Institute, Cairo University, Egypt.

Patients with oesophageal varices, gastrointestinal malignancies, co-morbidity, and contra-indication for endoscopy, patients on current anti-secretory drugs were excluded.

It is worth knowing that the group of patients with BE were retrieved from the Endoscopy Unit medical records and were subjected to follow-up endoscopic evaluation at the time of the study.

Patients were assigned into four groups according to the endoscopic and histopathological examination of the esophageal lesions:

Group I (GERD n=15): Eight males and seven females were suffering from different grades of GERD according to Los-Angeles classification [12].

Group II (Barrett's esophagus n=15): Eight males and seven females were suffering from Barrett's esophagus (BE) who were classified according to the presence of dysplasia [13] into non-dysplastic BE (BE-n) and dysplastic BE (BE-d).

Group III (EAC n=15): Data from ten males and five females, who were previously diagnosed from 2008-2011 as having EAC were obtained from the archives of Pathology Department, National Cancer Institute, Cairo University. Specimens were obtained from routine histopathologic work-up which had been performed under standardized conditions after surgical resection for EAC. Selection of these cases was based on the availability of the paraffin blocs and data. The material had been stored with permission of the local ethics committee, after informed consent obtained from the patients prior to previous endoscopic intervention.

Group IV (Control n=15): Nine males and six females who were suffering from symptoms suggestive of GERD (e.g., heart burn, dysphagia) and had normal esophageal endoscopic and histopathological examination were used as controls. Esophageal biopsies were obtained from any esophageal lesion in cases of GERD and Barrett's esophagus or from an area 3 cm above the Z line [14] in normal mucosa. Fresh oesophageal biopsies were rapidly fixed in neutral formalin, waxed in paraffin, sliced, rehydrated, and stained with H&E. Subsequently, two slides with a 4-micron thick tissue sections were sliced from every block for immunohistochemical staining for glutathione S-transferase P1 (GSTP1) and matrix metalloproteinase- 9 (MMP-9) tissue expressions.

The four micron thick tissue sections were dewaxed in Xylene and rehydrated through graded Ethanol. Endogenous peroxidase activity was blocked by incubation for 30 minutes at room temperature in 3% Hydrogen peroxide. After washing the sections three times in phosphate buffer saline (PBS) for five minutes, non-specific blocking was done with 1% bovine serum albumin (BSA)-PBS solution for ten minutes at room temperature.

Sixty slides were incubated with diluted polyclonal rabbit anti-human GSTP1 antibody (Thermo, Cat.: RB-050-R7) at 37°C for 60 minutes in a humidified chamber. The other sixty slides were incubated with optimally diluted monoclonal anti-human MMP-9 antibody (Thermo, Cat.: RB-9234-R7) at 37°C for 60 minutes in a humidified chamber. After washing the samples three times in PBS, signal conversion was carried out with the labeled streptavidin-biotin 2 (LSAB2) system as described in the manual of the antibody kit.

2.2 Immunohistochemical analysis of GSTP1 and MMP-9

Known immunohistochemically-positive tissue sections were used as positive controls; biliary epithelium in MMP-9 and breast cancer in GSTP1. Sections were processed immunohistochemically after having replaced the primary antibody by PBS. Immunostaining was determined qualitatively. Essentially, the intensity of staining for GSTP1 and MMP-9 under a light microscope was graded from 0 to 3, denoting no staining, light, moderate, or intense staining [10].

2.3 Statistical analysis

Data were presented as mean and standard deviation (SD) and percentage. The data were analyzed by SPSS version 14 (SPSS Inc., Chicago, IL, USA). The following tests of significance were used: *t*-test between means to analyze differences between means Differences between nominal variables were analyzed by χ^2 tests. Two-tailed *p*-value < 0.05 was considered statistically significant. Statistical analysis with one-way ANOVA, LSD test, and correlation analysis was performed. *P*-value <0.05 was considered significant.

3. Results

3.1 General patients characteristics

There was a male predominance in all groups without significant gender difference between all groups; *p*-value= 0.096, age of patients with EAC group was significantly higher than other groups(*p*-value < 0.001). Grades A and B of GERD were reported in 73.4% and 73.3% of Barrett's group had short (< 3 cm) segment BE. As regarding the control group, 53.4% had complete normal examination whereas 19.9% had duodenitis and 26.7% had gastritis (Table 1).BE was documented on histopathological basis with the evidence of dysplasia was documented in 7(46.6%) patients and all the EAC tissue biopsies demonstrated "grade 2" moderate differentiation.

We can demonstrate the intensity in pathology figures only without the need for table 2 and 3.

Table 1: Distribution of age, sex and endoscopic data among the studied patients and controls.

Variables	GERD	BE n=15		EAC	Control	p-value
	N=15	BE-n	BE-d	n=15	n=15	
Age mean±SD	38.93±5.52	39.75±4.92	41.43±10.66	65.4±11.64	41±10.36	0.001*
Sex n(%)						
Males	8(53.33)	5(62.5)	3(42.86)	10(66.7)	9(60)	0.096
Females	7(45.67)	3(37.5)	4(57.15)	5(33.3)	6(40)	
Endoscopic Data	Grades A 46.7% B 26.7% C 19.9% D 6.7%	Short (<3cm) 73.3% Long (>3cm) 26.7%		NA	Duodenitis 19.9% Gastritis 26.7% Normal 53.4%	NA

BE: Barrett's Esophagus, BE-d: BE with dysplasia, BE-n: BE without dysplasia, EAC: Esophageal Adenocarcinoma, GERD: Gastroesophageal Reflux Disease

Table 2: Intensity of esophageal tissue expression of MMP-9 among all groups(n=60).

Intensity of MMP-9 staining	GERD	BE n=15		EAC	Control	p-value
	n=15	BE-n	BE-d	n=15	n=15	
Negative (n=13)	2(13.3)	2(25)	0(0)	0(0)	9(60)	<0.001*
Light (n=15)	5(33.3)	3(37.5)	1(14)	0(0)	6(40)	
Moderate (n=14)	7(46.6)	2(25)	3(43)	2(13)	0(0)	
Intense (n=18)	1(6.8)	1(12.5)	3(43)	13(87)	0(0)	

BE: Barrett's Esophagus, BE-d: BE with dysplasia, BE-n: BE without dysplasia, EAC: Esophageal Adenocarcinoma, GERD: Gastroesophageal Reflux Disease. Values are expressed in n(%)

Table 3: Intensity of esophageal tissue expression of GSTP1 among all groups(n=60).

Intensity of GSTP1 staining	GERD	BE n=15		EAC	Control	p-value
	n=15	BE-n	BE-d	n=15	n=15	
Negative(n=14)	1(6.7)	0(0)	1(14.3)	12(80)	0(0)	<0.001*
Light (n=16)	4(26.7)	2(25)	6(85.7)	3(20)	1(6.7)	
Moderate (n=19)	8(53.3)	5(62.5)	0(0)	0(0)	6(40)	
Intense (n=11)	2(13.3)	1(12.5)	0(0)	0(0)	8(53.3)	

BE: Barrett's Esophagus, BE-d: BE with dysplasia, BE-n: BE without dysplasia, EAC: Esophageal Adenocarcinoma, GERD: Gastroesophageal Reflux Disease, Values are expressed in n(%)

3.2 MMP-9 immuno-histochemical tissue expression

Along the spectrum of esophageal lesions, MMP-9 expression was significantly lower in normal esophageal biopsies; p -value <0.001 in contrast to the significant higher expression in EAC biopsies compared to other groups; p -value <0.001 . Patients with dysplastic Barrett's esophagus (BE-d) had a significant higher MMP-9 expression as compared to non-dysplastic Barrett's esophagus (BE-n) and GERD; p -value <0.05 and <0.001 respectively (Figure 1).

Negative MMP-9 staining was detected in 60% of normal esophagus, 25% of patients with BE-n, 13.3% of GERD patients and none of patients with dysplastic BE and EAC. Intense MMP-9 staining was observed in 87% of patients with EAC, 43% of patients with dysplastic BE, 12.5% of patients with non-dysplastic BE, 6.8% of patients with GERD, and none of patients with normal esophagus (Table 2).

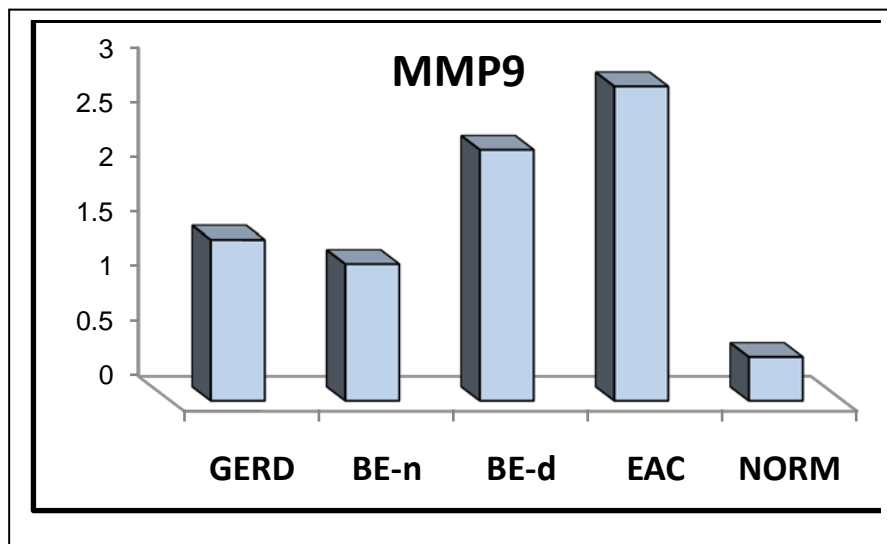


Figure 1. Esophageal tissue expression of MMP-9 in all studied groups.

BE: Barrett's Esophagus, BE-d: BE with dysplasia, BE-n: non-dysplastic BE, EAC: Esophageal Adenocarcinoma, GERD: Gastroesophageal Reflux Disease, NORM: normal

3.3 GSTP1 immuno-histochemical tissue expression

GSTP1 expression was significantly higher in normal esophageal biopsies; p -value <0.01 in contrast to the significant lower in expression in EAC biopsies compared to other groups; p -value <0.001 (Table 3). Patients with GERD and BE-n had a significant higher expression of GSTP1 as compared to BE-d; p -value <0.05 and <0.01 respectively (Figure 2).

Intense GSTP1 staining was observed in 53.3% of normal esophagus; 13.3% of GERD patients; 12.5% of BE-n and none of patients with dysplastic BE and EAC. No GSTP1 staining was observed in 80% of patients with EAC, 14.3% of patients with dysplastic BE, 6.7% of patients with GERD and none of patients with non-dysplastic BE and normal oesophagus (Table 3).

Patients' age was significantly correlated with both tissue expression of MMP-9 and GSTP; p -value < 0.001 respectively. On the other hand, patients' gender did not elicit such significance, p -value 0.72, 0.85 respectively.

Simultaneous evaluation of both tissue expression MMP-9 and GSTP1 in the same esophageal specimen revealed an inverse correlation; $r = -0.762$ and p -value < 0.001 . (figure 3).

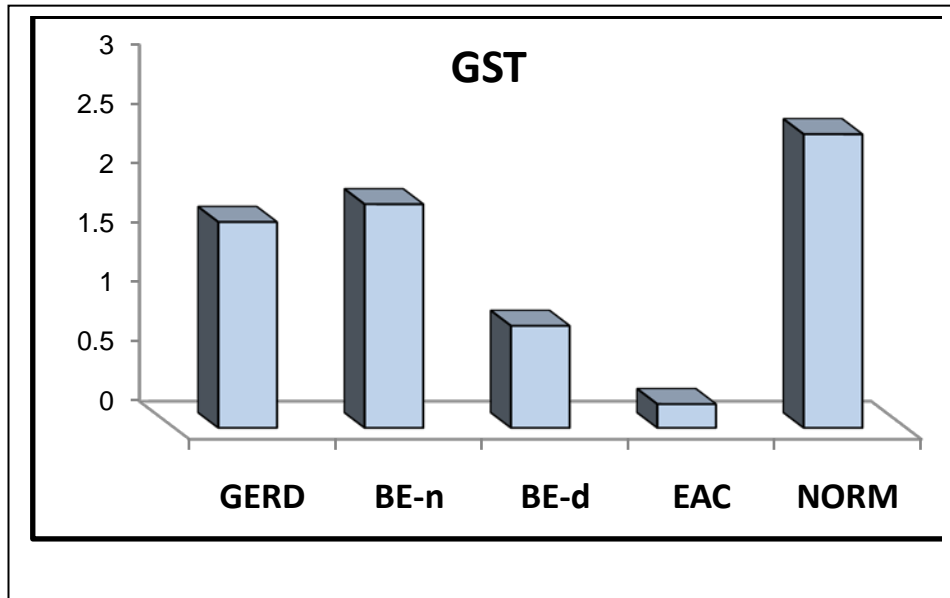
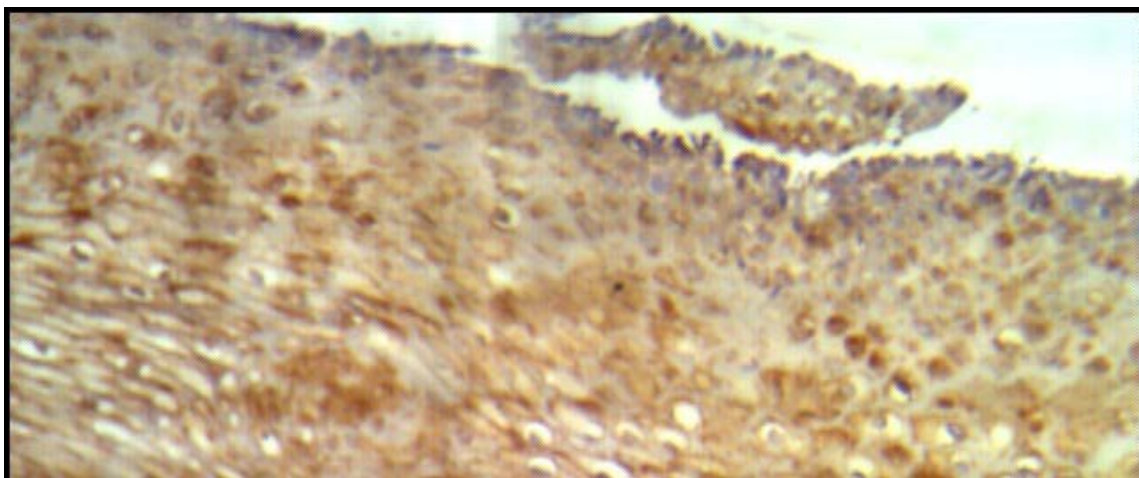


Figure 2. Esophageal tissue expression of GSTP1 in all studied groups.

BE: Barrett's Esophagus, BE-d: BE with dysplasia, BE-n: non-dysplastic BE, EAC: Esophageal Adenocarcinoma, GERD: Gastroesophageal Reflux Disease NORM: normal.



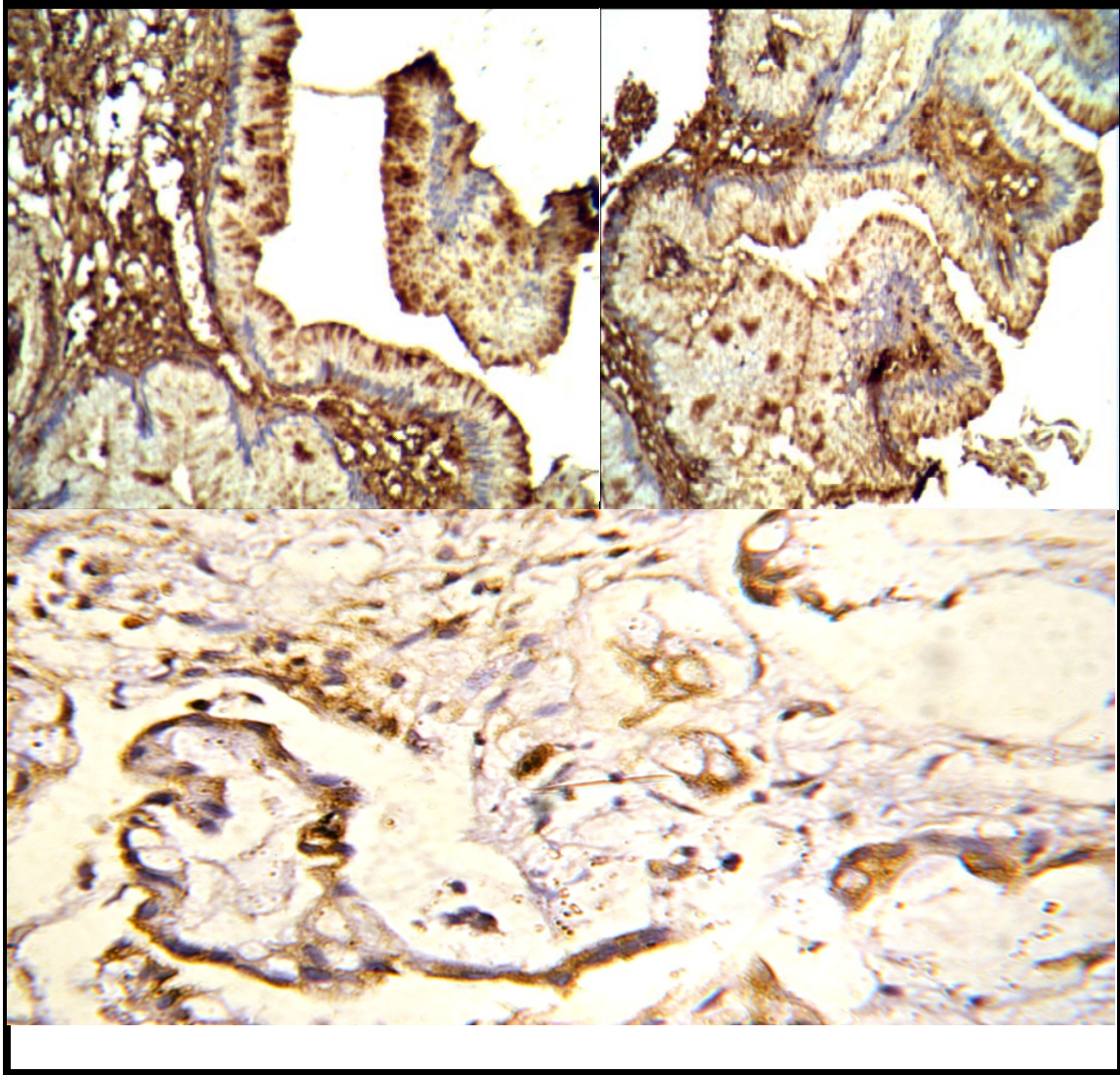


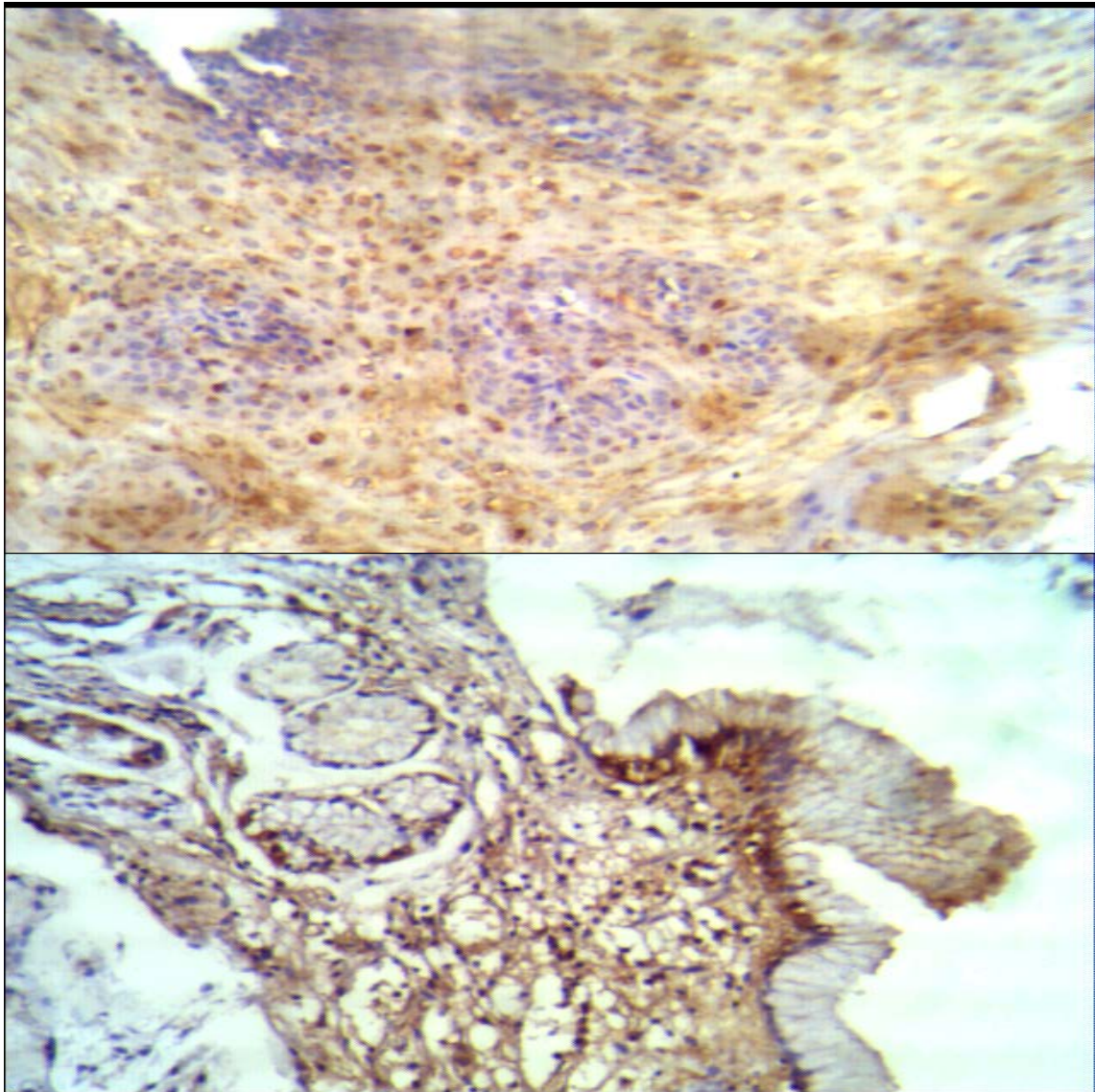
Figure (3): Expression of MMP-9 in different esophageal tissues. A) No MMP-9 staining in normal esophageal epithelium (100×); B) Barrett's esophagus showed moderate staining (200×); and C) Esophageal adenocarcinoma showing intense MMP-9 expression (400×); MMP-9 was mainly expressed within the cytoplasm.

4. Discussion

Analyzing the data of MMP-9 and GSTP1 esophageal expressions in our study demonstrated that normal esophageal epithelium expressed the lowest MMP-9 expression and the highest GSTP1 expression in contrast to their expression in esophageal adenocarcinoma and patients with dysplastic Barrett's epithelium which are considered to be pre-malignant conditions. On the other hand, among patients with GERD and non-dysplastic Barrett's esophagus, who are potentially non-malignant, there was no significant difference in the expressions of both MMP-9 and GSTP1. In accordance with our results, the reduction in GST as represented by GSTP1 which is the most important isoform in esophagus and increase proteolytic enzymes in which MMP-9 plays crucial role can increase the risk of carcinogenesis [10].

The rise of MMP-9 expression was related to the increase in severity of esophageal lesions with highest level of MMP-9 expression in EAC and dysplastic BE. This may be attributed to a multi-step increase in MMP-9 level according to its desired function starting from chemokine and cytokine release passing to cleavage of cell surface receptors, release of apoptotic ligands, growth factor release, angiogenesis, and eventual basement membrane destruction. Moreover, the exhaustion and failing of the inhibitory system of MMP-9; namely tissue inhibitor of matrix metalloproteinases (TIMPs), reaching the lowest level in adenocarcinoma [15].

The decrease of GSTP1 between normal esophageal epithelium and adenocarcinoma may be attributed to the possibility of GSTP1 gene mutation early in the sequential multi-step DNA mutation involved in adenocarcinoma carcinogenesis. So, the esophageal epithelium will be vulnerable to cytotoxic and oxidant stresses transforming the cellular environment to lakes of DNA damage without any anti-oxidant activity which will end in cancer [16].



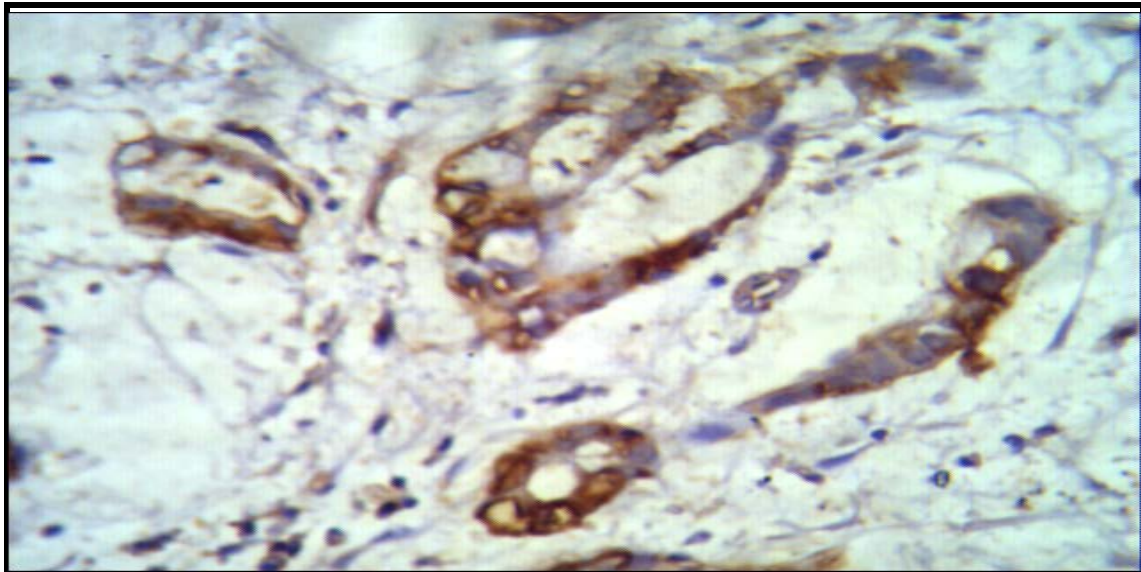


Figure (4): Expression of GSTP1 in different esophageal tissues. A) GST intense positive staining in normal esophageal epithelium (200×); B) Barrett's esophagus showed light GST staining (400×); and C) Esophageal adenocarcinoma showing almost no expression of GST (400×); GST was mainly expressed within the cytoplasm.

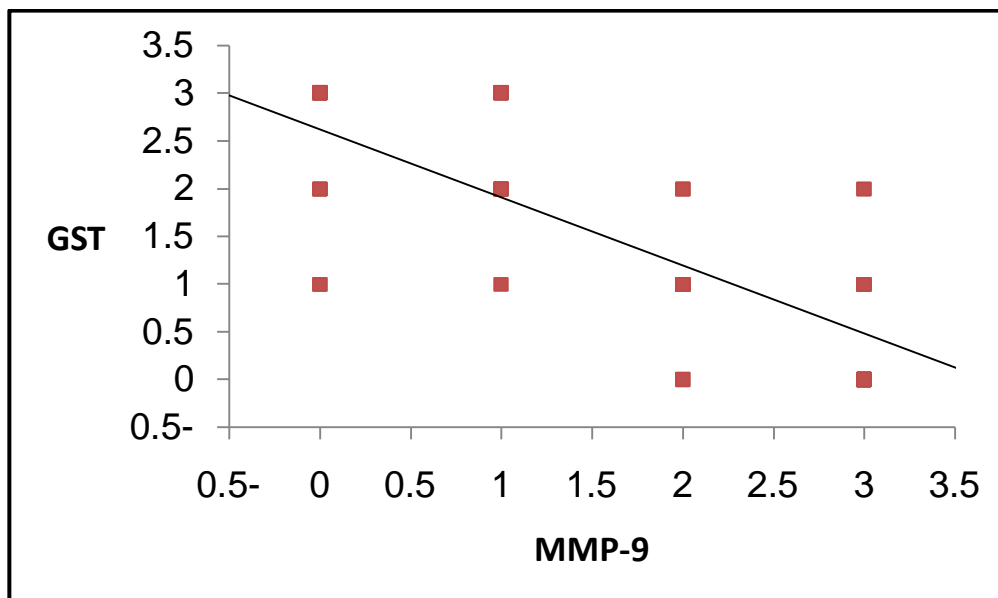


Figure 5. Simultaneous immunohistochemical tissue expression of both MMP-9 & GSTP1 expression in all patients.

As regarding the GSTP1 observation, our results are consistent with Levy and his colleagues, and other previous studies [17-20]. They reported a higher significant GSTP1 expression in normal esophageal epithelium in comparison to reflux esophagitis, Barrett's esophagus, and esophageal adenocarcinoma. Also, *Herszenyi and his colleagues* [10] and *Peng and his colleagues* [21] reported the same sequential GSTP1 down-regulation through

normal esophageal epithelium, GERD, Barrett's esophagus, and adenocarcinoma sequence. All authors attributed this down-regulation as a potential important mechanism in Barrett's carcinogenesis.

On the other hand, increased GSTP1 expression in esophageal adenocarcinoma as reported by *Chandra and his colleagues* [22] and *Zhu and his colleagues* [23] who described a sequential increase of GSTP1 expression in normal esophagus-hyperplasia-dysplasia-esophageal cancer sequence. They attributed their findings to GSTP1 protection of the tumor cells themselves from the cytotoxic effects of free radicals. However, their findings could not be explained.

As regarding the MMP-9 observation, our results are consistent with those published by *Auvinen and his colleagues* [24] and *El-Kenawy and his colleagues* [25]. They reported a significant lower MMP-9 expression in normal esophageal epithelium in comparison to Barrett's adenocarcinoma. Also, *Herszenyi and his colleagues* [10] and *Mroczko and his colleagues* in [26], stated the same significant sequential up-regulation in MMP-9 expression in normal esophageal epithelium, compared to GERD, Barrett's esophagus, and esophageal adenocarcinoma sequence. All authors attributed this up-regulation to the role of MMP-9 in angiogenesis, basement destruction, and carcinogenesis.

The near absence of MMP-9 in normal healthy esophageal epithelium appeared to be requested for establishing tissue integrity, unsuitable environment for cancer development, and helping in renewal and repairing of esophageal epithelium beside a well-functioning powerful inhibitory system of MMP-9 (TIMPs) [15]. Our results agree with those published by previous studies [24,27,28] as they reported low MMP-9 expression in normal esophageal epithelium.

This could be explained by that the extreme adverse effect of MMP-9, namely basement membrane destruction, apoptosis loss, and angiogenesis needed the highest expression of MMP-9. Complete loss of inhibitors of MMP-9 (TIMPs) could also be an explanation for this observation [29].

Finding higher GSTP1 in normal esophageal epithelium is due to higher anti-oxidant activity in normal cells to withstand internal and external cytotoxins and oxidative stresses maintaining cell integrity and providing healthier nuclear and cytological structures. Subsequent GSTP1 decrease leads to accumulation of reactive oxygen species and DNA damage which will end in adenocarcinoma. In 2009, *Peng and his colleagues* demonstrated a moderate to strong immunostaining of GSTP1 in normal esophageal samples and attributed this to a higher antioxidant system in normal esophagus in comparison to adenocarcinoma [21].

As regarding the observation of lower GSTP1 expression in adenocarcinoma, it could be attributed to exhaustion and failing of GST system rendering the DNA vulnerable to any cytotoxin and oxidative stress will end in multiple mutations and carcinogenesis [11].

As associated with a higher risk of esophageal adenocarcinoma, specimens with dysplastic Barrett's esophagus were separately analyzed. MMP-9 staining intensity ranged from light-to-intense while GSTP1 staining intensity ranged from negative-to-light. We found a significantly higher MMP-9 expression and a significantly lower GSTP1 expression in cases suffering from Barrett's esophagus with concomitant dysplasia in comparison to

non-dysplastic Barrett's, GERD, and normal esophageal epithelium. Also, a significant higher GSTP1 and lower MMP-9 expressions were also observed in dysplastic Barrett's esophagus in comparison to patients with esophageal adenocarcinoma. These observations clarify that the activation of MMP-9 and the loss of GSTP1 may be early events in adenocarcinoma carcinogenesis and pathogenesis.

Simultaneous analysis of both GSTP1 and MMP-9 tissue expressions in each esophageal specimen revealed a concomitant down-regulation of the former which was coupled by up-regulation of the latter. Thus a balance between GSTP1 as a member of detoxifying and MMP-9 as a proteolytic enzyme is postulated to prevent carcinogenesis.

5. conclusion

In conclusion, this is the first study done on Egyptian to evaluate the tissue expression of MMP-9 and GSTp1 in esophageal lesions. The quantification of these parameters in Barrett's esophagus; a potential malignant condition might be useful to identify patients at higher risk for progression to cancer.

References:

- [1] von Rahden BHA, HJ S: Barrett's Esophagus and Barrett's Carcinoma. *Curr GERD Rep*; 1: 125-32.2007.
- [2] Spechler SJ: Clinical practice. Barrett's Esophagus. *N Engl J Med*, 346(11):836-42. 2002.
- [3] Shaheen N: Is there a "Barrett's iceberg?". *Gastroenterology*, 123(2):636-9. 2002.
- [4] Ronkainen J, Aro P, Storskrubb T, Johansson SE, Lind T, Bolling-Sternevald E, Vieth M, Stolte M, Talley NJ, Agréus L. Prevalence of Barrett's esophagus in the general population: an endoscopic study. *Gastroenterology*.;129(6):1825-31. Dec2005.
- [5] Roberts KJ, Harper E, Alderson D et al. Long-term survival and cost analysis of an annual Barrett's surveillance programme. *Eur J Gastroenterol Hepatol*.; 22 (4): 399-403. 2010.
- [6] Reid BJ, Haggitt RC, Rubin CE, Roth G, Surawicz CM, Van Belle G, Lewin K, Weinstein WM, Antonioli DA, Goldman H, et al. Observer variation in the diagnosis of dysplasia in Barrett's esophagus. *Hum Pathol*.;19(2):166-78. Feb. 1988.
- [7] Huang Q and Hardie LJ. Biomarkers in Barrett's oesophagus. *Biochem Soc Trans*. ; 38 (2): 343-347. 2010.
- [8] Sternlicht MD, Werb Z. How matrix metalloproteinases regulate cell behavior. *Annu Rev Cell Dev Biol*.;17:463-516. 2001
- [9] Olaso E, Lin HC, Wang LH et al. Impaired dermal wound healing in discoidin domain receptor 2-deficient mice associated with defective extracellular matrix remodeling. *Fibrogenesis Tissue Repair*.; 4 (1): 5. 2011.
- [10] Herszenyi L, Hritz I, Pregon I et al: Alterations of glutathione S-transferase and matrix metalloproteinase-9 expressions are early events in esophageal carcinogenesis. *World J Gastroenterol*.; 13 (5): 676-682. 2007.
- [11] Wang Z, He W, Yang G, Wang J, Wang Z, Nesland JM, Holm R, Suo Z. Decreased expression of GST

- pi is correlated with a poor prognosis in human esophageal squamous carcinoma. *BMC Cancer*. 5;10:352-9. Jul. 2010
- [12] Lundell LR, Dent J, Bennett JR et al Endoscopic assessment of esophagitis: clinical and functional correlates and further validation of the Los Angeles classification. *Gut*; 45 (2): 172–180. 1999.
- [13] Wolf C (2010): Case of month. Barrett's esophagus. *JAAPA*; 23 (7): 65.
- [14] Gatopoulou A, Mimidis K, Giatromanolaki A et al: Impact of Helicobacter pylori infection on histological changes in non-erosive reflux disease. *World J Gastroenterol* 10 (8): 1180-1182. 2004.
- [15] Hwang YS, Park KK, and Chung WY: Kalopanaxsaponin a inhibits the invasion of human oral squamous cell carcinoma by reducing metalloproteinase-9 mRNA stability and protein trafficking. *Biol Pharm Bull.*; 35 (3): 289-300. 2012.
- [16] Danyelle M, Kenneth D, and Haim T: The importance of glutathione in human disease. *Biomedicine & Pharmacotherapy*; 57: 145–155. 2003.
- [17] Levy RD, Oosthuizen MM, Degiannis E, Greyling D, Hatzitheofilou C. Glutathione-linked enzymes in benign and malignant oesophageal tissue. *Br J Cancer.*; 80(1-2):32-7. Apr. 1999.
- [18] Fu B, Zhang Y, Wang Y. Expression of GST-pi gene in human esophageal carcinogenesis. *Zhonghua Zhong Liu Za Zhi.*; 21(1):29-31. (Abstract) Jan. 1999.
- [19] Brabender J, Lord RV, Wickramasinghe K, Metzger R, Schneider PM, Park JM, Hölscher AH, DeMeester TR, Danenberg KD, Danenberg PV. Glutathione S-transferase-pi expression is downregulated in patients with Barrett's esophagus and esophageal adenocarcinoma. *J Gastrointest Surg.*; 6(3):359-67. May-Jun. 2002
- [20] Cobbe SC, Scobie GC, Pohler E, Hayes JD, Kernohan NM, Dillon JF. Alteration of glutathione S-transferase levels in Barrett's metaplasia compared to normal oesophageal epithelium. *Eur J Gastroenterol Hepatol.*; 15(1):41-7. Jan. 2003.
- [21] Peng DF, Razvi M, Chen H, Washington K, Roessner A, Schneider-Stock R, El-Rifai W. DNA hypermethylation regulates the expression of members of the Mu-class glutathione S-transferases and glutathione peroxidases in Barrett's adenocarcinoma. *Gut.*; 58(1):5-15. Epub. Jan. 2009.
- [22] Chandra RK, Bentz BG, Haines GK 3rd, Robinson AM, Radosevich JA. Expression of glutathione s-transferase pi in benign mucosa, Barrett's metaplasia, and adenocarcinoma of the esophagus. *Head Neck.*; 24(6):575-81. Jun. 2002
- [23] Zhu X, Zhang SH, Zhang KH, Li BM, Chen J. Value of endoscopic methylene blue and Lugol's iodine double staining and detection of GST-Pi and telomerase in the early diagnosis of esophageal carcinoma. *World J Gastroenterol.* 21;11(39):6090-5. Oct. 2005