



---

## Multidisciplinary Oral Management in Cancer Therapy Part I: Pre-Surgical Management

Manu Rathee<sup>a\*</sup>, Mohaneesh Bhoria<sup>b</sup>, Priyanka Boora<sup>c</sup>

<sup>a,b,c</sup> *Department of Prosthodontics, Post Graduate Institute of Dental sciences, Pt. B. D. Sharma University of Health Sciences, Rohtak, Haryana, India*

<sup>a</sup> *Email: ratheemanu@gmail.com*

<sup>b</sup> *Email: mohaneesh83@gmail.com*

<sup>c</sup> *Email: ashoo612@rediffmail.com*

### Abstract

Oral cavity suffers a short-term and long-term complication from cancer therapy. An appropriate evaluation and elimination of potential source of oral infection before cancer therapy is vital and must. The best management strategy encompasses a prophylactic local and systemic combination therapy that has implications for post-treatment oral comfort and function, thus promoting consistent high standards of oral care through a co-ordinated team approach is warranted. This paper provides a multidisciplinary oral management prior to cancer therapy.

**Keywords:** Cancer therapy; Oral care; Oral prophylaxis.

### 1. Introduction

The management of dental diseases before cancer therapy poses many challenges to dental practitioners. Oral cavity has been common ground of short-term and long-term complications from cancer therapy that may require modification of dental management strategy. Dental treatment may also require modifications in situations where it must be delivered expeditiously and little time to institute an ideal treatment plan. As stated there is insufficient time period between diagnosis of cancer and commencement of cancer treatment.

---

\* Corresponding author.

E-mail address: ratheemanu@gmail.com.

This shortage of time along with failure to consider the oral implication at high priority often compromises complex emergency invasive dental treatments. Hence, it is warranted that patients and carers are educated and motivated about oral care procedures [1]. Hence, a pathway of management should be considered and executed under as immediate therapy phase and followed by reassessment phase. Immediate therapy phase is aimed at identifying etiological factors, relieving sensitivity and pain and protecting remaining oral hard and soft tissue. Although, full compliance may be difficult. At very least a “Damage Limitation” pathway can be initiated. This involves the identification, control and referral for advice relating to problem under consideration. Consideration should be given as diet analysis and counselling to control or reduce the effect of aetiological factors, prescription of neutral, sodium fluoride mouthrinses or gel for daily use, direct application of glass ionomer and/or composite to sensitive areas, thorough oral prophylaxis, consultation with oncologic team for further referral. The reassessment phase should include whether the original aetiological factors are eliminated/ stabilize to cause no further damage. Reassessment period involves review & monitoring of oral conditions and be should at least be equivalent to the period of monitoring of cancer by the Oncology team. (Figure 1)

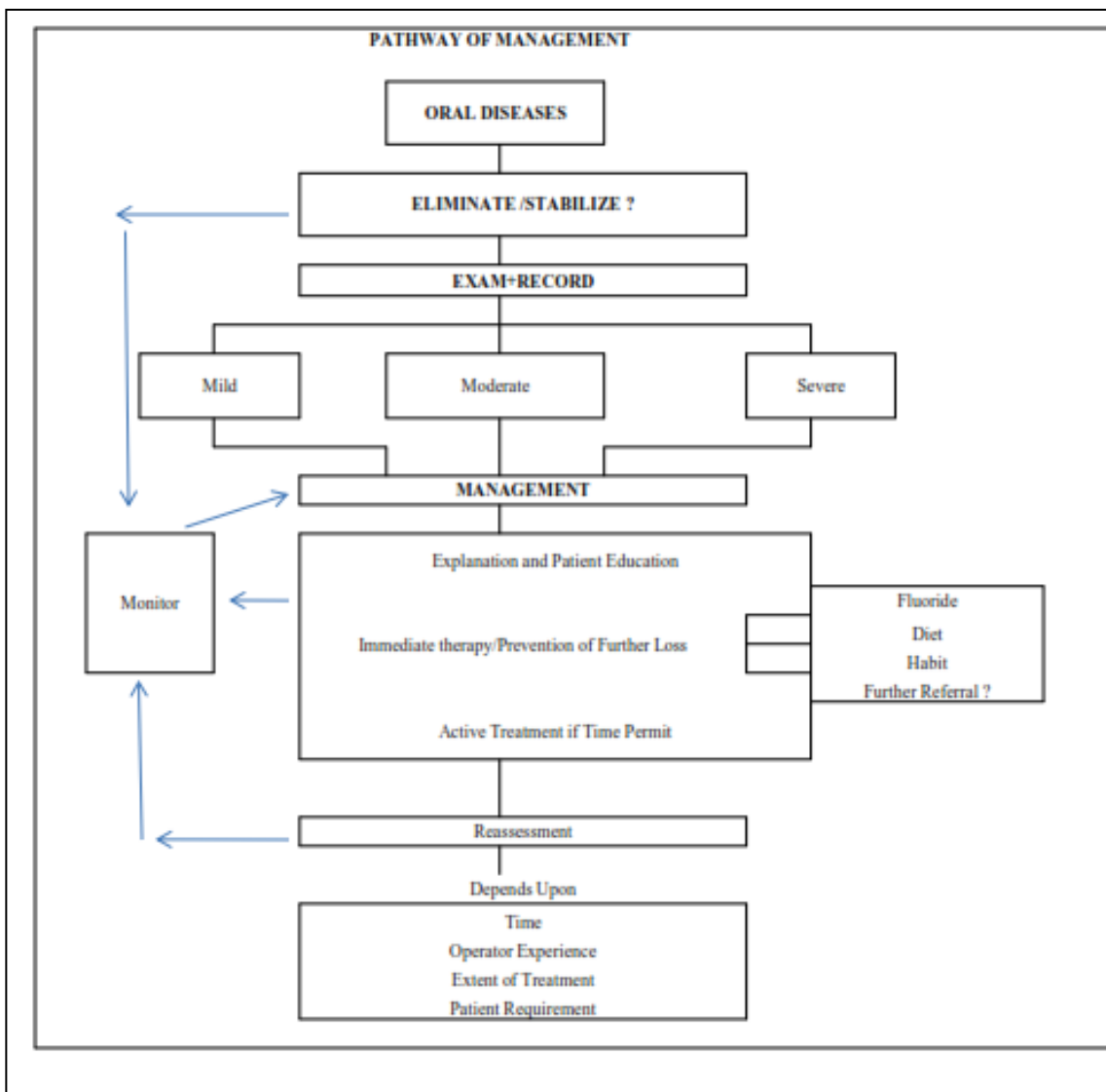


Figure 1. Oral Assessment and Management prior to cancer therapy

## **2. Oral management of a patient in preparation for cancer therapy**

### **2.1 Pre-treatment oral evaluation**

Pre-treatment oral evaluation depends on the cancer diagnosis and planned cancer therapy. The patients most frequently seen before chemotherapy or radiation are those with highest risk for developing short-term and long-term complications. This includes the patient undergoing chemotherapy followed by hematopoietic stem cell transplantation (HSCT). These patients are at high risks for infectious complications during the period of pancytopenia. Another group includes patients who require head and neck radiation therapy. Radiation at therapeutic doses induces long-term irreversible damage to hard & soft tissue of oral cavity and associated glands and, in particular the mandible [2].

Ideally, a comprehensive oral evaluation should take place 1 month before cancer treatment to allow adequate recovery time from any required invasive dental procedures. A comprehensive oral assessment should be done as this will help to identify existing oral disease and potential risk of oral disease, remove infectious dental/oral foci before the start of cancer therapy, prepare the patient for expected side effects of cancer therapy, establish an adequate standard of oral hygiene to meet the increased challenge, develop a plan for maintaining oral hygiene, providing preventive care and follow-up, establish the necessary multidisciplinary collaboration to reduce/alleviate oral symptoms and sequelae before, during and after cancer therapy.

As noticed there is no universally accepted pre-cancer therapy dental protocol because of the lack of clinical trials evaluating the efficacy of a relevant cancer therapy related protocol [3, 4].

- Teeth in direct association with the tumour or the radiation beam and teeth with doubtful prognosis should be extracted before radiotherapy. Teeth should be removed with a minimum of trauma and if possible primary closure achieved. Ideally allow three weeks for maximal healing time before radiotherapy. Ten days should be considered a minimum period [5, 6].
- Any faulty restorations or sharp edges of teeth should be reduced to decrease the risk of trauma to the associated oral mucosa [7].
- The use of an aqueous alcohol free chlorhexidine mouthwash (10ml of 0.2% aqueous alcohol free chlorhexidine gluconate mouthwash or 18ml of 0.12% aqueous chlorhexidine gluconate solution twice daily for at least one week prior to commencing treatment) or dental gel in combination with thorough oral hygiene practices showed evidence that it reduces the incidence of oral complications. In children chlorhexidine is rarely used unless toothbrushing cannot be performed [8].
- When maxillary surgery is to be combined with radiotherapy, diagnostic casts should be prepared for obturator planning in liaison with the surgical team.
- Where time permits it is preferable to restore teeth with a permanent restorative material. During limited time period glass ionomer cements make an effective restoration.
- For children the recommendations for oral care at the time of diagnosis has been made which involve the removal of all primary teeth within three months of exfoliation and those with any risk of pulpal involvement [4]. The children are advised to brush at least twice a day, with fluoride toothpaste appropriate and in accord to the age and toothbrush should be changed on either a three month basis or when bristles splay, if earlier and especially, following an oral infective episode. If the child has a sore

mouth a soft brush with a small head should be used [8, 9]. Children need to be helped or supervised by an adult until at least 7 years of age, parents/carers should be instructed on how to brush their child's teeth. For babies without teeth, parents/carers should be instructed on cleaning the mouth with oral sponges/soft brush or gauze as temporary measure. These items should be moistened with water or an antimicrobial agent such as diluted alcohol-free chlorhexidine. The need to restrict sugary food and drink to meal times only should be emphasised. Children undergoing orthodontic therapy should have their orthodontic appliance removed and treatment discontinued until one year after completion of cancer treatment [10].

- For adults, a restorative and reconstructive dentist should work with the surgeon as a multidisciplinary team, especially if surgery to the jawbone is planned. It has been reported that 78% of patients experience severe difficulties in mastication following major head and neck surgery [11]. Oral surgical procedures should be performed at least seven to ten days before the patient receives myelosuppressive chemotherapy. Oncologic consultation is indicated prior invasive procedures [8]. Guidelines for extractions, endodontic treatment, and other dental interventions can be used as suitable [11, 12].

However, if the patient were gravely ill and dental treatment would delay chemotherapy, indicated dental treatment by necessity will need to be postponed until the patient is between courses of chemotherapy and when haematological value permit. Such scenario occurs particularly, in that case of a haematologic malignancy. In all such cases, consultation with the managing physician is warranted to determine the patient's ability to undergo the anticipated dental therapy.

### **3. Conclusion**

Patient education and motivation should be an integral part of the pre-treatment evaluation and should include a discussion of potential oral complications. It is must that the dental team imprints on the patient regarding optimal oral hygiene practice during treatment, avoiding tobacco and alcohol and adequate nutrition can minimise post-treatment oral complications and reduce recurrence/further cancers. It is warranted that dental team should ensure that the patient fully recognition of signs of complications, understands detailed instructions on specific oral care practices, and other instructions suitable for the individual. Such pre-treatment oral care and function is an important contributor to post-treatment social adaptation and life quality. Hence, appropriate preventive regimens and timely oral care can minimize complications and improve quality of life.

### **References**

- [1] Peterson, D.E., Sonis, S.T. Oral complications of cancer chemotherapy. Present status and future studies. *Cancer Treatment Reports*, Vol. 66, pp. 1251-1256, 1982.
- [2] Meurman JH, Gronroos L. Oral and dental health care of oral cancer patients: hyposalivation, caries and infections. *Oral Oncology*, Vol. 46, pp. 464-467, 2010.
- [3] M.J. Shaw, N.D. Kumar, M. Duggal, J. Fiske, D.A. Lewis and T. Kinsella et al., Oral management of patients following oncology treatment: literature review. *Br J Oral Maxillofac Surg*, Vol. 38 (5), pp. 519-524, 2000.

- [4] Fayle, S.A., Duggal, M.S., Williams, S.A. Oral problems and the dentists role in the management of paediatric oncology patients. *Dental Update*, pp. 152-159, May 1992.
- [5] Clayman, L. Clinical controversies in oral and maxillofacial surgery: Part two. Management of dental extractions in irradiated jaws: a protocol without hyperbaric oxygen. *J Oral. Maxillofacial Surg*, Vol. 55, 275-281, 1997:
- [6] Makkonen T.A., Kimnki A, Makkoness T.K., Nordman E. Dental extractions in relation to radiation therapy of 224 patients. *Int J Oral Maxillofac Surg*. Vol. 16, pp.56, 1987.
- [7] Joshi V.K. Dental treatment planning and management for the mouth cancer patient. *Oral Oncol*. Jun, Vol. 46(6), pp. 475-9, 2010.
- [8] Rutkauskas J.S., Davis J.W. Effects of chlorhexidine during immunosuppressive chemotherapy. A preliminary report. *Oral Surg. Oral Med. Oral Pathol*, vol. 76, pp 441-448, 1993.
- [9] Joyston-Bechal, S. Prevention of Dental Diseases following Radiotherapy and Chemotherapy. *Int. Dent. J.*, Vol. 42, pp. 47-53, 1992.
- [10] Sheller, B, Williams, B, Orthodontic management of patients with haematological malignancies. *Am.J.Orthod.Dentofac.Orthop*. Vol. 109, pp. 575- 80,1996.
- [11] Overholser C.D., Peterson D.E., Bergman S.A., et al.: Dental extractions in patients with acute nonlymphocytic leukemia. *J Oral Maxillofac Surg*, Vol. 40 (5), pp. 296-8, 1982.
- [12] Williford SK, Salisbury PL 3rd, Peacock JE Jr, et al.: The safety of dental extractions in patients with hematologic malignancies. *J Clin Oncol*, Vol.7 (6), pp. 798-802, 1989.