
Surgical Treatment of Important Pelvic Organ Prolapse in a Patient with Severe Systemic Disease: A Case Report

Marco Gentile^{a*}, Mariaconcetta Zinna^b, Antonio Costanza^c, Giacomo Miola^d,
Andrea Remo^e, Marco Torrazzina^f

^{a,b,c,f}Obstetrics and Gynecology Unit, Department of Mother and Child, ULSS 9 "Scaligera", Legnago 37045,
Verona, Italy

^dAnesthesiology and Intensive Care Unit, Emergency Department, ULSS 9 "Scaligera", Legnago 37045,
Verona, Italy

^ePathology Unit, Service Department, ULSS 9 "Scaligera", San Bonifacio 37047, Verona, Italy

^aEmail: marco-gentile@hotmail.it

Abstract

Pelvic Organ Prolapse (POP) is a common disease and the surgical treatment ranges from traditional vaginal techniques to abdominal approach using mesh. We present a case of a woman with severe POP and with severe systemic disease treated with vaginal surgical approach under regional anesthesia. A 56-years-old woman presented to our hospital with a POP. The patient had HIV infection and chronic hepatitis C with liver fibrosis. She had a previous STEMI and a subsequent NSTEMI. The surgery performed was vaginal hysterectomy with bilateral salpingo-oophorectomy, anterior and posterior vaginal repair, right sacrospinous ligament fixation, under regional anesthesia. Prevalence of POP ranges from 10% to 24% and vaginal correction of defects is a common procedure, but Cochrane review stated that abdominal mesh surgery should be considered the gold standard for the treatment but this surgery needs general anesthesia. Because the recurrence of prolapse after vaginal hysterectomy and sacrospinous ligament fixation occurred in approximately 25%, this technique could be useful in patients with systemic disease under regional anesthesia and a multidisciplinary approach is essential.

Keywords: POP; anesthesia; hysterectomy; sacrospinous.

* Corresponding author.

1. Introduction

Pelvic Organ Prolapse (POP) is a common disease and often it is a multicompartamental disorder. A recent study predicted that, by the year 2050, 43.8 millions of women in the USA could be affected by at least one pelvic floor disorder [1]. The surgical treatment of POP ranges from traditional vaginal techniques to abdominal approach using mesh. The open mesh sacrocolpopexy is widely considered to be the gold standard technique for the repair of high grade POP [2] and the introduction of laparoscopy and then robotic surgery has provided a minimally invasive option to open pelvic surgery with similar outcomes [3]. These recent surgical options require in most cases general anesthesia and conventionally general anesthesia remains the choice for the majority of open abdominal surgical procedures [4]. Regional anesthesia is preferred only for patients who are at high risk using general anesthesia and for patient with a severe systemic disease [4]. Regard to treating women with POP and severe systemic disease it could be useful to use a multidisciplinary approach and to choose more traditional vaginal techniques using regional anesthesia [5]. We present a case of a woman with severe POP and with severer systemic disease treated with vaginal surgical approach under regional anesthesia.

2. Case Report

A 56-years-old Caucasian woman G1P001 presented to our hospital with a severe pelvic organ prolapse. She had last menstruation four years before. The patient was non-smoker and she had a BMI of 21 kg/m². She denied drinking alcohol or using drugs. The main symptoms were sensation of vaginal pressure, constipation, dyspareunia and embarrassment during sexual activity. She didn't refer stress or urge incontinence. The past medical history was very important. The patient had HIV infection, A3 clinical category according to CDC classification system and chronic hepatitis C with stage 3 liver fibrosis (F3) according to Metavir scoring system. She had also previous cholecystectomy, severe hypothyroidism and major depressive disorder, but the most important pathology was a previous ST Elevation Myocardial Infarction (STEMI) treated with percutaneous transluminal coronary angioplasty (PTCA) and plain old balloon angioplasty (POBA). Subsequently the patient had Non ST Elevation Myocardial Infarction (NSTEMI) managed with conservative treatment. At gynaecological assessment she had a defect of anterior, middle and posterior compartment, and according to Pelvic Organ Prolapse Quantification system (POP-Q) a stage IV was diagnosed (Figure 1). Bladder stress test and Bonney test were negative. Coloproctological visit confirmed fourth-degree rectocele. Ultrasound exam showed a 5 mm endometrial thickness and both normal ovaries. Diagnostic hysteroscopy and endometrial biopsy were performed and the histopathological exam showed atypical endometrial hyperplasia. The preoperative anesthesiological visit showed a class 3 American Society of Anesthesiologists physical status classification (ASA PS 3) and a multidisciplinary (gynaecologists, coloproctologists, cardiologists, infectivologists, anesthesiologists took part) evaluation of case was performed. The surgery proposed and then performed was vaginal hysterectomy with bilateral salpingo-oophorectomy, anterior and posterior vaginal wall repair, right sacrospinous ligament fixation. The operation was conducted during spinal anesthesia (Figure 2). The final histopathological exam confirmed the atypical endometrial hyperplasia and normal Fallopian tubes and ovaries. At three-months and six months follow-up visits the patient had not pelvic organ prolapse and she referred a significant improvement in sexual function and defecation.

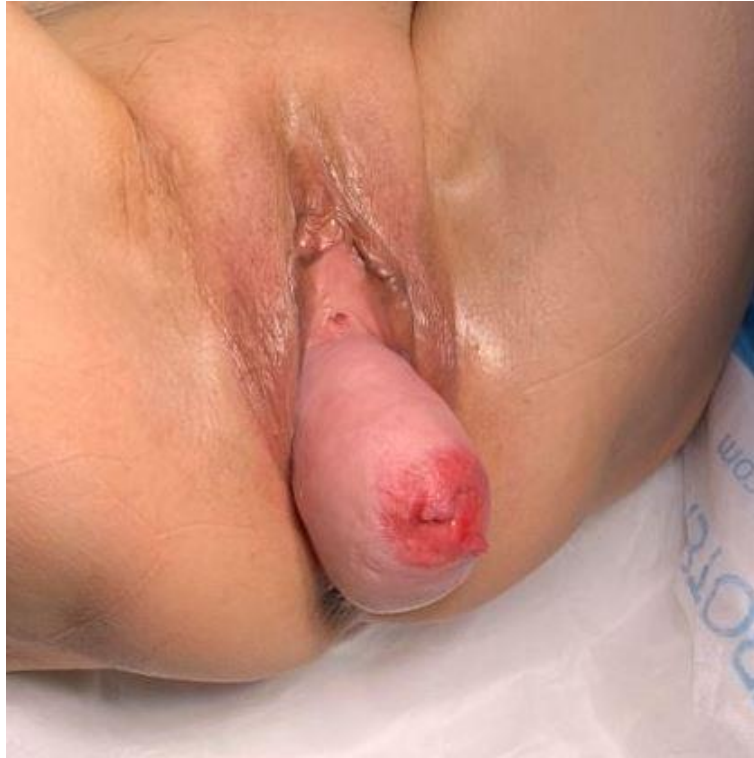

Figure 1: Pelvic Organ Prolapse

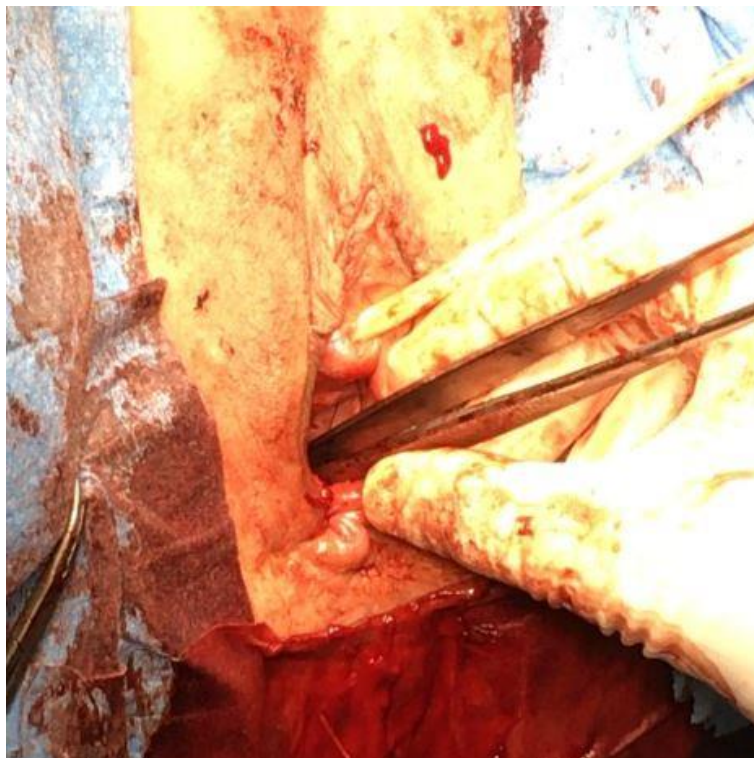


Figure 2: Final aspect after surgery

3. Discussion

POP is a very common pathology and it regards an increasing number of women. Its prevalence ranges from 10% to 24% [6] and risk factors for this pathology are increased age, obesity, multiparity, previous hysterectomy [7-8]. The main symptoms of POP are urinary or fecal incontinence, constipation, dyspareunia, pelvic pain [7,9]. Vaginal hysterectomy associated with correction of anterior or posterior vaginal defects is a common procedure for correcting prolapse but vaginal vault prolapse is the main complication of this kind of surgery with an incidence of 11.6% [10]. For this reason it is often necessary to perform the vaginal vault suspension procedure during hysterectomy. McCall's Culdoplasmy or sacrospinous fixation can be performed with similar outcomes at the time of vaginal hysterectomy to reduce the recurrence [11]. A recent Cochrane review stated that abdominal sacrocolpopexy should be considered the gold standard in the treatment of apical prolapse [2]. In a recent review it was found that long-term failures rates for abdominal sacrocolpopexy range from 0% to 26% [12]. Cochrane collaboration and National Institute for Clinical Excellence (NICE) recommended abdominal sacrocolpopexy as more effective procedure for apical prolapse and this procedure can be performed either open or using laparoscopic or robot assisted surgery with similar outcomes [13]. A similar surgical technique is the sacrocervicopexy and it can be performed after supracervical hysterectomy. This technique has a 91.8% success rate [10] and it has similar long term failure rates compared to abdominal sacrocolpopexy [12]. These abdominal procedures should be performed under general anesthesia and it could be a problem in high risk patients. There are no absolute contraindications to general anesthesia but there are many relative contraindications. The patient's medical condition should be maximized preoperatively. For example, a patient with unstable angina should undergo cardiac catheterization or bypass prior to elective surgery [14]. For this reason the use of regional anesthesia reduce the incidence of some major complications as deep vein thrombosis, pulmonary embolism, myocardial infarction, respiratory depression, pneumonia, renal failure [15]. Another study conducted on 50 patients suggested that spinal anesthesia reduced duration of operation (1.93 hours vs 1.95 hours) and amount of blood loss (250.34 ml vs 625.0 ml) compared to general anesthesia in patient that underwent vaginal hysterectomy [16]. At the same time the Cochrane Database Review noted that abdominal sacral colpopexy was associated with lower rates of recurrent apical prolapse and dyspareunia than vaginal sacrospinous fixation but these benefits were negatively balanced from longer operative time and longer time to return to activities of daily living [2]. In a recent study, moreover, a recurrence of prolapse after vaginal hysterectomy and sacrospinous ligament fixation occurred in approximately 25% within 5 years, and the need for repeat surgery was 17% [17]. In consideration of clinical history of the patient, the calculated time of operation, the advantages in this case of a spinal anesthesia and after a multidisciplinary evaluation of the case we decided to perform a vaginal hysterectomy with bilateral salpingo-oophorectomy, anterior and posterior vaginal wall repair, right sacrospinous ligament fixation. The duration of surgery was 90 minutes and the blood loss was 300 ml. No recurrences were at six-months follow up, but a long term follow up could be necessary. In a recent study Singh and his colleagues showed that laparoscopic surgeries are feasible and safe under combined spinal and epidural anesthesia (of 50 patients only 2 had conversion to general anesthesia) but further larger randomized controlled trials are required [18]. An interesting recent study reviewed the outcome of vaginal hysterectomy and pelvic floor repair using local anesthesia (lidocaine infiltration) and supplementary analgesia (pentazocine injection) with 72.2% of patients satisfied for the technique [5]. However for this anesthetic option

a large, randomized and controlled study is recommended.

4. Conclusions

The role of surgical diagnosis in the choice of anesthetic technique is very important. A good multidisciplinary preoperative evaluation and perioperative close monitoring could minimize the potential risks in patient with severe systemic disease.

5. Conflict of interest

The authors declare no conflict of interest

References

- [1]. Wu, J.M., Hundley, A.F., Fulton, R.G. and Myers, E.R. (2009) Forecasting the prevalence of pelvic floor disorders in U.S.Women: 2010 to 2050. *Obstet Gynecol* 114: 1278_1283.
- [2]. Maher C, Feiner B, Baessler K, Schmid C. Surgical Management of Pelvic Organ Prolapse in Women. *Cochrane Database Syst Rev* 2013 Apr 30;(4)
- [3]. Gilleran JP, Johnson M, Hundley A. Robotic-assisted laparoscopic mesh sacrocolpopexy. *Ther Adv Urol.* 2010 Oct-Dec; 2(5-6): 195–208.
- [4]. Sinha R, Gurwara AK, Gupta SC, Laparoscopic Surgery Using Spinal Anesthesia. *JLS.* 2008 Apr-Jun; 12(2): 133–138.
- [5]. Onafowokan O, Asemota O. Vaginal hysterectomy using local anesthesia and analgesics. *Trop J Obstet Gynaecol* 2016; 33 (3): 270-273
- [6]. Martín Del Olmo JC, Toledano M, Martín Esteban ML, Montenegro MA, Gómez JR, Concejo P et al. Outcomes of Laparoscopic Management of Multicompartmental Pelvic Organ Prolapse. *Surg Endosc.* 2019; 33 (4): 1075-1079
- [7]. Samuelsson EC, Victor FT, Tibblin G, Svärdsudd KF. Signs of genital prolapse in a Swedish population of women 20 to 59 years of age and possible related factors. *Am J Obstet Gynecol.* 1999; 180:299–305
- [8]. Barber MD. Pelvic organ prolapse. *BMJ.* 2016; 354: i3853
- [9]. Van Zanten F, Brem C, Lenters E, Broeders IAMJ, Schraffordt Koops SE. Sexual Function After Robot-Assisted Prolapse Surgery: A Prospective Study. *Int Urogynecol J.* 2018; 29 (6), 905-912
- [10]. Rosati M, Bramante S, Bracale U, Pignata G, Azioni G. Efficacy of Laparoscopic Sacrocervicopexy for Apical Support of Pelvic Organ Prolapse. *JLS* Apr-Jun 2013;17(2):235-44.
- [11]. Rajan D, Varghese P, Roy M, Roy K, David A. Is Performing Sacrospinous Fixation With Vaginal Hysterectomy and McCall's Culdoplasty for Advanced Uterovaginal Prolapse Preferable Over McCall's Culdoplasty Alone? *J Obstet Gynaecol India* 2020 Feb;70(1):57-63
- [12]. Ganatra AM, Rozet F, Sanchez-Salas R, et al. The current status of laparoscopic sacrocolpopexy: a review. *Eur Urol.* 2009; 55:1089 –1105.

- [13]. Freeman RM, Pantazis K, Thomson A, Frappell J, Bombieri L, Moran P et al. A Randomised Controlled Trial of Abdominal Versus Laparoscopic Sacrocolpopexy for the Treatment of Post-Hysterectomy Vaginal Vault Prolapse: LAS Study. *Int Urogynecol J*. 2013; 24 (3): 377-84
- [14]. Eichelsbacher C, Ilper H, Noppens R, Hinkelbein J, Loop T. Rapid Sequence Induction and Intubation in Patients With Risk of Aspiration : Recommendations for Action for Practical Management of Anesthesia. *Anaesthesist* 2018 Aug;67(8):568-583
- [15]. Yuzkat N, Soyoral L, Cegin MB, Ozkan B, Goktas U. The Role of Surgical Diagnosis in The Choice of Anesthetic Technique. *Eur J Gen Med* 2016;13(2):158-160
- [16]. Pranoto I. The Evaluation of Vaginal Hysterectomy Using Spinal Anaesthesia. *J Med Sci*. 2007; 39 (2)
- [17]. Gupta P. Transvaginal Sacrospinous Ligament Fixation for Pelvic Organ Prolapse Stage III and Stage IV Uterovaginal and Vault Prolapse. *Iran J Med Sci* 2015 Jan;40(1):58-62
- [18]. Singh RK, Saini AM, Goel N, Bisht D, Seth A. Major laparoscopic surgery under regional anesthesia: A prospective feasibility study. *Med J Armed Forces India*. 2015 Apr; 71(2): 126–131